



[Science Archives \(ISSN:2582-6697\)](http://www.sciencearchives.org)

Journal homepage: www.sciencearchives.org



<http://dx.doi.org/10.47587/SA.2022.3210>

Research Article



Therapeutic effect of *Hibiscus sabdariffa linn* on some physiological variables in male white mice exposed to oxidative stress

Raghad Hazem Alabbasy

Department of Pathological Analysis, College of Applied Sciences, University of Samarra, Iraq

*Corresponding author: raghad.h@uosamarra.edu.iq

Received: May 14, 2022/ Revised: June 18, 2022 / Accepted: June 21, 2022

Abstract

This study was carried out to investigate the therapeutic effect of the water extract of the *Hibiscus sabdariffa lin* and its effect as an antioxidant on some physiological variables in male white mice exposed to oxidative stress induced by ethanol. Twenty adult white male mice aged 2-3 months were used with weights ranging from 20-30 g, divided into four groups of 5 rats per group. The groups were as follows: control group (G1), second group (G2) was given 5% of ethanol and the third group (G3) was given ethanol and water extract for *Hibiscus sabdariffa lin* at a concentration of 10%, and (G4) group was given ethanol and water extract of *Hibiscus sabdariffa lin* at a concentration of 20.

Keywords Therapeutic, *Hibiscus sabdariffa lin*, Male White Mice, Oxidative Stress

Introduction

Oxidative stress is one of the factors that causes atherosclerosis and insufficiency of vascular function, as it contributes significantly to damage to the lining cells. Ox-LDL works on the development of atherosclerosis lesions (Anderson, 2003). The injury of the body to certain diseases or the occurrence of any dysfunction causes imbalances in the exact balance between oxidants and antioxidants, thus leading to oxidative stress, a state of imbalance between the concentration of a number of effective reactive oxygen intermediates and the defensive ability of various mechanisms present in the cells of the body tissue, specialized in the disposal of free radicals leading to an increase in fat peroxidation and then the damage of the various tissues of the body (Prince et al., 2007), effective oxygen have the ability to destroy large biomolecules within the cell Such as carbohydrates, proteins and DNA particles leading to many diseases such as neurological diseases, cardiovascular diseases, cerebral stroke, arthritis and kidney disease as well as genetic mutations and reduction of internal antioxidant levels such as SOD (Szekanecz et al., 2007) natural products have entered the forefront of attention and scientific research because of its protection and prevention against toxins and

carcinogens, and in recent decades, there has been increasing interest in the use of alternative and complementary medicine. Medical plants have become important in reducing the development of many diseases (Arai et al 2000). More than one-third of the world's population uses herbs for therapeutic and preventive purposes. Many medicinal plants have been used to treat heart disease, gastrointestinal disorders, liver, and central nervous system disorders, (Sathiyarayanan and Arulmozhi 2007). One of these plants *Hibiscus sabdariffa lin* is used in this study, and it is one of the best-known medicinal plants in many countries. It is used as a diuretic, antipyretic and anti-bacterial, as well as for the treatment of gastrointestinal disorders, high blood pressure, and high cholesterol (Sabu and Kuttan 2002). The research indicated that it contains antioxidants and chemopreventive substances (Chen et al., 2007), so this study was designed to reach the following:

1. Induce a state of oxidative stress and observe that from some blood parameters.
2. Strengthen the state of internal antioxidants in animals exposed to oxidative stress.

Material and Methods

Experimental Animals

Twenty adult male mice are aged 2-3 months were used with weights ranging from 20-30 g. The animals were raised in a special room with the right conditions for raising animals from feeding, temperature, lighting, and ventilation.

The animals were divided into 4 groups with 5 animals per group and treated for 30 days as follows:

G1: Regular drinking water was given throughout the test period and considered as a control group.

G2: was given drinking water containing ethanol at a concentration of 5% for the duration of the experiment.

G3: Drinking water containing 5% ethanol was given for two weeks, then ethanol was cut off and the water extract of the *Hibiscus sabdariffa lin* was given at a concentration of 10% for two weeks.

G4: Drinking water containing 5% ethanol was given for 2 weeks and then water extract of *Hibiscus sabdariffa lin* was given at 20% concentration for two weeks.

Collecting of blood samples

After the end of the experiment period (30 days), the blood was taken from the animals in a slaughtering manner and (1 cm³) of blood was placed in a plastic tube with a strong cover containing Ethylene Diamine Tetra Acetic Acid (EDTA) which is anticoagulant substance to for blood film tests include the measurement of the total number of red blood cells count (RBCs), as well as the measurement of changes in hemoglobin (HB), the packed cells volume of blood (PCV) and the total number of white blood cells (WBCs), these tests were performed using Alpha-Celttac-Japanese origin.

Statistical Analysis

Results were statistically analyzed using the statistical analysis package social science system (SPSS) according to Duncan multiple range test *with* a significant concentration ($P \leq 0.05$).

Results and Discussion

General behavior of experimental animals

The ethanol-treated animals suffered from low food intake, inactivity, and a significant weight reduction. These changes may be due to poor intestinal absorption, as well as abdominal pain, which negatively affects the animal's ability to eat. These effects may be the result of the oxidative effort resulting from the accumulation of free radicals from ethanol treatment, which leads to the death of the majority of the nuclei of the cells as indicated by the researcher.

While the two groups treated with the water extract of the *Hibiscus sabdariffa lin* showed an improvement in the rate of consumption of food, which is similar to the control animals. This may be due to the possibility of the water extract of the *Hibiscus sabdariffa lin* to repair the damage caused by the treatment with ethanol and the treatment of various types of infections (Bruske et al., 2006) also.

Blood tests

Table 1. The tests conducted on research groups

Groups Tests	G1	G2	G3	G4
RBC 10 ³ ul	4.4 a	2.9 B	4.28 a	4.33 a
dl /HBg	12.7 a	10.1 C	12 b	12.5 a
PCV%	42.6 a	33.9 C	37.9 b	42.3 a
WBC count (cell/ ml3)	5.26 a	3.19 B	5.29 a	5.62 a

*Small horizontal letters indicated a significant on ($P \leq 0.05$).

Red blood cell count (RBC)

The results of this study showed a significant decrease in the total number of red blood cells (RBC) in the group (G2) which amounted to (2.9) while the group (G3) (G4) showed no significant differences which amounted to (4.28) (4.33) as compared with the control group (G1) which amounted to (4.40).

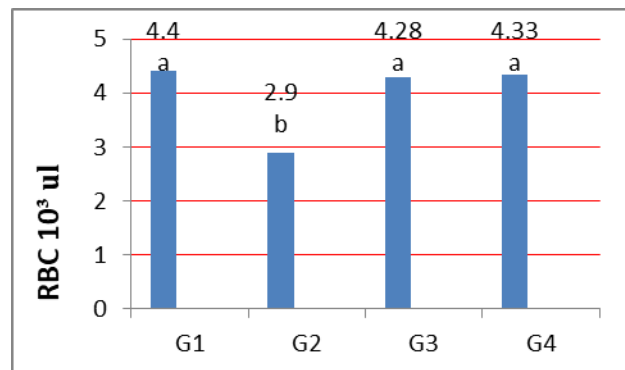


Fig. 1 Changes in the red blood cells count (RBC)

A significant decrease in the total number of red blood cells may be due to the generation of active oxygen groups that have affected inhibiting the formation of red blood cells by contravention the work of many hormones, including thyroid hormones, which also affect the production of Erythropoietin hormone by kidney and then effect on bone marrow and the formation of red blood cells and thus reduce the number of red blood cells (Fig. 1). The results of the group (G3 and G4)

indicates the cellular reform of this compound and its ability to get rid of free radicals as it contains a tetralogy, which assists in cellular repairing processes (Kim et al., 2007).

Changes in Hemoglobin (Hb) Rate

The results showed a significant decrease in the hemoglobin rate in the group(G2) (G3) which amounted to (10.1) (12.0), while the group (G4) showed no significant differences which amounted to (12.5) when compared with the hemoglobin rate of the control group (G1) which amounted to (12.7) (Fig. 2).

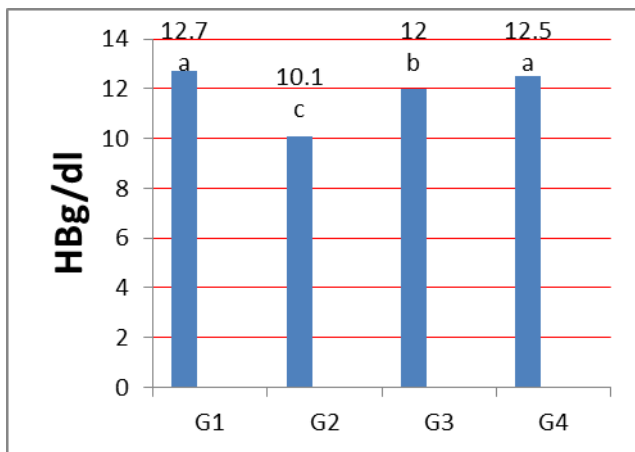


Fig. 2 Changes in the hemoglobin rate (Hb)

The results of the study showed a significant decrease in the concentration of hemoglobin (HB) in the ethanol treatment group, which may be due to the generation of effective oxygen classes produced by oxidative stress and resulting in the oxidation of sulfur groups (-SH) in the peptide chain of the protein of hemoglobin and the formation of di-sulfuric bonds and thus oxidation of iron (Fe + 2) to the ferric (Fe + 3) and this is what the researcher pointed out (Babu et al 2003).

The results of the group treated with water extract of the *Hibiscus sabdariffa lin* at a concentration of 10% showed a significant decrease compared to the control but differed significantly from the group of ethanol alone, perhaps because the concentration used contributed to the cellular repair, but was not enough to reach the normal limit and this is consistent with what (Al-Kaisy, 2014) point out.

The results of the group treated with ethanol and then treated with water extract of the *Hibiscus sabdariffa lin* at a concentration of 20%, has shown the ability of the extract to repair the damage resulting, as it contains many of the materials that possess the properties of anti-oxidation and inflammation, including flavonoids, which is one of the products of secondary metabolism, which have a significant impact in the capture of free radicals resulting from the effect of peroxide as indicated by the researcher (Pujiastuti, 2016).

Packed Cell Volume (PCV)

The results of this study showed a significant decrease in the concentration of Packed Cell Volume (PCV) in the group (G2) (G3) which amounted to (33.9) (37.9) compared with the control group which amounted to (42.6), while the group (G4) no significant differences which amounted to (42.3).

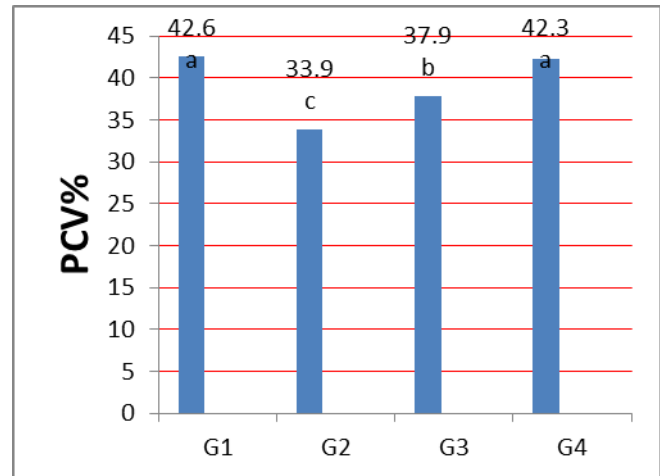


Fig. 3 Changes in the packed cell volume (PCV)

A decrease in the (PCV) of the ethanol treatment group may be due to attacking the free radicals generated by the use of ethanol for red blood cell membranes as well as the oxidation of fat forming these membranes and thus the breakdown of pellets, which is reflected on the size of blood cells. The results of the treatment group with ethanol first and then the water extract of the *Hibiscus sabdariffa lin* at 10% concentration and 20% concentration indicate the possibility of disposal of the animal from oxidative damage and the possibility of compensation for damaged cells and repair damage caused by the process of oxidation caused by ethanol and the water extract of the *Hibiscus sabdariffa lin* rich in many compounds that have an impact in repair, it is rich in vitamins such as riboflavin (vit. B2), ascorbic acid (vit. C), niacin, thymine, and carotene, as well as content on organic acids such as malic acid, hibiscus acid, tartaric acid, and citric acid (Fig. 3). This has an important effect in reducing the inflammation in the body and this is consistent with what (Mensah and Golomeke 2015) mentioned.

Total count of white blood cells (WBCs)

The results showed a significant decrease in the total count of white blood cells (WBCs) in the group (G2) which amounted to (3.19) when compared to control group (G1) which amounted to (5.26), while no significant differences in group (G3) (G4) which amounted to (5.29) (5.62).

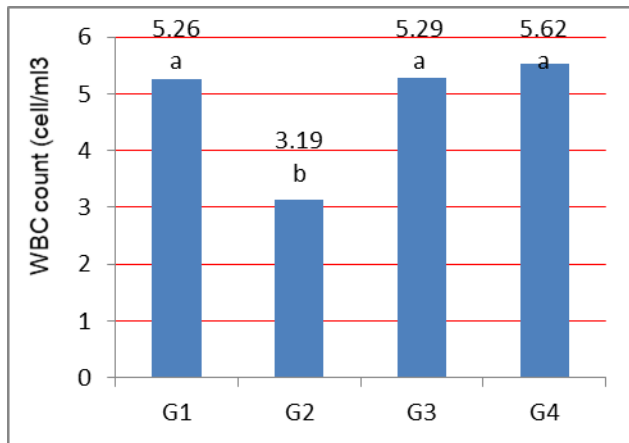


Fig.4 Changes in the total number of white blood cells (WBCs)

A significant decrease in the total number of white blood cells in the ethanol group (G2) may be due to the direct effect of oxidative stress and the effect of free radicals on white blood cell membranes, thus accelerating and increasing (Fig. 4). Apoptosis, which is one of its causes is the exposure to chemical compounds and therefore its effect on the immune response leading to the lack of numbers of cells, this result is not consistent with (Shi et al., 2008) which indicated an increase in the number of white blood cells when treated with ethanol, while the group treated with water extract (G3 and G4) did not show significant differences and this is reffer to high-quality for water extract components to repair the damage caused by the ethanol and reducing inflammation occurring in the body and thus return to the normal cells intact, and this is corresponding with what referred to by (Al Asmari et al., 2016).

Conflict of Interest

The author hereby declares no conflict of interest.

Funding support

The author declares that they have no funding support for this study

Ethical Considerations

The study was approved by the institutional ethical committee

References

- Al Asmari, A., Al Shahrani, H., Al Masri, N., Al Faraidi, A., Elfaki, I., & Arshaduddin, M. (2016). Vanillin abrogates ethanol induced gastric injury in rats via modulation of gastric secretion, oxidative stress and inflammation. *Toxicology reports*, 3, 105-113.
- Anderson, J. W. (2003). Whole grains protect against atherosclerotic cardiovascular disease. *Proceedings of the Nutrition Society*, 62(1), 135-142.
- Arai, Y., Watanabe, S., Kimira, M., Shimoi, K., Mochizuki, R., & Kinai, N. (2000). Dietary intakes of flavonols, flavones and isoflavones by Japanese women and the inverse correlation between quercetin intake and plasma LDL cholesterol concentration. *The Journal of nutrition*, 130(9), 2243-2250.
- Babu, T. S., Akhtar, T. A., Lampi, M. A., Tripuranthakam, S., Dixon, D. G., & Greenberg, B. M. (2003). Similar stress responses are elicited by copper and ultraviolet radiation in the aquatic plant *Lemna gibba*: implication of reactive oxygen species as common signals. *Plant and Cell Physiology*, 44(12), 1320-1329.
- Brüske-Hohlfeld, I., Rosario, A. S., Wölke, G., Heinrich, J., Kreuzer, M., Kreienbrock, L., & Wichmann, H. E. (2006). Lung cancer risk among former uranium miners of the WISMUT Company in Germany. *Health physics*, 90(3), 208-216.
- Chen, H. Y., Lin, Y. C., & Hsieh, C. L. (2007). Evaluation of antioxidant activity of aqueous extract of some selected nutraceutical herbs. *Food chemistry*, 104(4), 1418-1424.
- Kim, J. K., So, H., Youn, M. J., Kim, H. J., Kim, Y., Park, C. & Park, R. (2007). Hibiscus sabdariffa L. Water extract inhibits the adipocyte differentiation through the PI3-K and MAPK pathway. *Journal of ethnopharmacology*, 114(2), 260-267.
- Mensah, J. K., & Golomeke, D. (2015). Antioxidant and antimicrobial activities of the extracts of the Calyx of Hibiscus Sabdariffa Linn. *Current Science Perspectives*, 1(2), 69-76.
- Prince, M., Ferri, C. P., Acosta, D., Albanese, E., Arizaga, R., Dewey, M. & Uwakwe, R. (2007). The protocols for the 10/66 dementia research group population-based research programme. *BMC public health*, 7(1), 1-18.
- Pujiastuti, E. (2016). Pengaruh fraksi etil asetat kulit batang juwet (*Syzygium cumini* L.) Terhadap penurunan kadar glukosa darah pada tikus diabetes mellitus tipe II resistensi insulin. *Jurnal Keperawatan dan Kesehatan Masyarakat Cendekia Utama*, 5(1).
- Sabu, M. C., & Kuttan, R. (2002). Anti-diabetic activity of medicinal plants and its relationship with their antioxidant property. *Journal of ethnopharmacology*, 81(2), 155-160.
- Sathiyarayanan, L. & Arulmozhi, S. (2007). *Mucuna pruriens* Linn.-A comprehensive review. *Pharmacognosy Reviews*, 1(1), 157-161.
- Shi, L. J., Han, H. L., & Zhang, S. X. (2008). Virus Location and Lymphocyte Apoptosis in Lymph Nodes of Piglets Infected with PCV-2. *Agricultural Sciences in China*, 7(4), 507-512.
- Szekanecz, Z., Kerekes, G., Der, H., Sandor, Z., Szabo, Z., Vegvari, A. & Soltész, P. (2007). Accelerated atherosclerosis in rheumatoid arthritis. *Annals of the New York Academy of Sciences*, 1108(1), 349-358.

How to cite this article

Alabbasy, R. H. (2022). Therapeutic Effect of *Hibiscus sabdariffa* lin on Some Physiological variables in Male White Mice Exposed to Oxidative Stress. *Science Archives*, Vol. 3 (2), 139-42. <http://dx.doi.org/10.47587/SA.2022.3210>

This work is licensed under a [Creative Commons Attribution 4.0 International License](https://creativecommons.org/licenses/by/4.0/)



Publisher's Note: MD International Publishing stays neutral with regard to jurisdictional claims in published maps and institutional affiliations