



## Histopathological effect of ranitidine (Zantac) on liver and kidneys in albino mice

Muna Salah Rashid 

Department of Biology, Collage of Science, University of Tikrit, Salah Al-deen, Iraq

Received: Feb 2, 2023/ Revised: Mar 4, 2023/ Accepted: Mar 5, 2023

(✉) Corresponding Author: [muna.salah@tu.edu.iq](mailto:muna.salah@tu.edu.iq)

### Abstract

This study was sought to determine the effect of ranitidine on the histological structure of liver and kidneys in albino mice. Two groups of mice were administered Ranitidine 75mg/kg of and 150 mg/kg respectively, we used (15) albino mice and administrated the doses orally for 10 consecutive 10 days. The results showed some structural effects on tissues of liver and kidneys group two showed (75 mg/kg of b. w.) desquamation of the wall of central vein of the liver, necrosis, accumulation of fibroblast, hemorrhage, and aggregation of Kupffer cells. The kidneys exhibited necrosis in some regions, hemorrhage and existence of cast in the tubules and it seems that ranitidine has caused dilation between glomerulus and bowman corpuscles. Group three (150 mg/kg of b. w.) revealed more damage in the wall of the central vein of the liver, infiltration of focal inflammatory in the area caused hemorrhage, expansion in sinusoid, accumulation of fibroblast and necrosis in the liver tissue. Kidneys were severely affected in comparison to group one and showed an extended hemorrhage and ruptures in glomerulus with dilatation, hyperplasia cells in tubules and cast, from this study we conclude that ranitidine with a dose of 75mg/kg has mild effect on the liver and kidneys and medium effect with a dose of with a dose of 150 mg/kg. The research is focus in histopathology effects of ranitidine on liver and kidneys

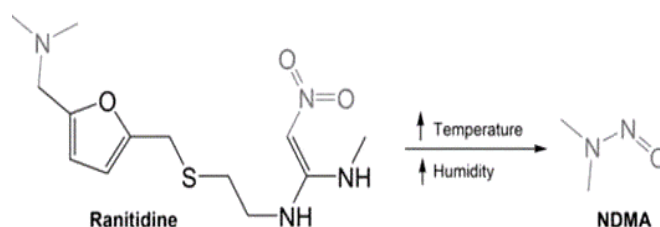
**Keywords:** Ranitidine, Liver, Kidneys, Necrosis, Fibroblast

### Introduction

In April 2020, the FDA decided to withdraw all counter ranitidine (zantac) drug from pharmacies after claims that it contains certain levels of N-nitrodimethylamine (NDMA). (Woodcock, 2019).

NDMA, a potential carcinogen, is a natural substance, which occurs in small amounts in bodies, processed foods and treated water. Although several medications that contain NDMA are still available, ranitidine has been immediately withdrawn from the shelves. Later on, it was found that the levels of NDMA in ranitidine increased over time (Wagner and Colombo, 2020). Therefore, many researchers were sought to study and analyze Ranitidine components using high throughput analytical technologies. Investigations revealed that the elevated level of NDMA was attributed to the

degradation of Ranitidine molecules over time due to improper storage during hot and humid seasons and exposure to disinfectants found in drinking water (Fig 1) (King et al., 2020).



**Fig. 1:** Showing the slow degradation of ranitidine and form of NDMA by heat and humidity (Fiona et al., 2020)

After low amounts of the possible human carcinogen N-nitrosodimethylamine (NDMA) were detected in certain batches of over-the-counter ranitidine tablets (75mg and 150mg), the US Food and Drug Administration has asked patients and doctors to return drugs (FDA, 2019).

The FDA advance information to the public and doctors, declaring that some ranitidine medications may comprise low levels of NDMA and requesting that any tablets labelled by Walgreens, Walmart, or Rite-Aid and manufactured by Apotex Corporation be returned, as well as recalling 14 lots of medication ranitidine capsules spread by Sandoz, Novartis' generic division, for the same reason (Mahase, 2019)

NDMA is a recognized human carcinogen that has the potential to cause cancer. It's a well-known pollutant that can be found in water and foods such as meat, dairy, and vegetables (FDA, 2019).

Clinical examination of side effects of Zantac are very similar to the symptoms recorded by placebo, according to French reports, The most common side effects are: clay-colored stools, dark urine, loss of appetite, coughing with mucous, increase heart beat, weakness, vertigo and dizziness, also can cause liver failure and kidney failure (Llamas, 2021)

Due to these factors, the aim of this research was to determine the effect of ranitidine in the histological structures of the liver and kidneys in albino mice.

## Materials and methods

### Animals

Fifteen male albino mice (*Mus musculus albinus*), 5 weeks of age, weighing  $25 \pm 3$  g were purchased from the animal house of college of Veterinary Medicine, University of Tikrit, Iraq. The mice were kept for 7 days in cages under controlled conditions of temperature ( $25 \pm 2^\circ\text{C}$ ) and light (12hrs/12hrs) at the university animal house and were given standard food pellets and water. All animals were used in the experiment.

### Drug preparation

Ranitidine tablets were purchased from local pharmacies as Zantac<sup>R</sup> hydrochloride 75 mg/kg bw and 150 mg/kg bw. Tablets were crushed without any further purification, dissolved in normal saline and administered to the animals orally with the given dosages.

### Experimental design

Animals were divided into three groups 5 mice each, group one is the control group and administered distilled water orally for 10 days. Groups 2 and 3 were the treatment groups and administered 57 mg/kg and 150 mg/kg bw normal saline suspension of ranitidine orally for 10 days. Animals were

subjected to daily monitoring and weights were taken before and after the experiment. At the end of the experiment, the animals were anesthetized, dissected and the liver and kidneys were stored with formalin 10% for the subsequent experiment.

## Tissues preparation

Tissues preparation was performed according to the method described (Suvarna, and Bancroft, 2019) Briefly, all sections were fixed with formalin 10%, and dehydrated once with ethanol 50, 70, 90, 96 % and twice with 100% for 30 minutes each concentration. Afterward, sections were cleared with xylol, infiltrated and embedded in paraffin wax. Subsequently tissues were subjected to sectioning by rotary microtome (Microtec- Rotary Microtome Cut4060 - Germany), and stained with hematoxylin and eosin. Finally, slides were made, mounted by DPX, examined by light microscope (OBL-137C832DIGITAL MICROSCOPE SET 4x-100x with 3W LED (transmitted light), with Tablet camera 5mp, WLAN, USB 2.0, HDMI, SD, CMOS 1/2,5" inclusive of C-MOUNT ADAPTER), and processed by Photoshop (Adobe Photoshop CC 2021, USA).

## Results and discussion

### Effect of Ranitidine on the liver

In group one, control group, the liver has normal, the central vein and the hepatocytes were normally arranged as a cord regulated around the central vein, the sinusoid between the hepatocytes cords and could see the Kupffer cells in the sinusoids (Fig. 2A). In group two, that has been treated orally with Ranitidine 75mg /kg, the liver has been mildly affected. Liver showed necrosis in some areas, desquamation of the wall of central vein, aggregations of fibroblasts, hemorrhage due to desquamation, hepatocytes were normally arranged with the presence of Kupffer cells (Fig 2-B).

Group two, where animals treated with Ranitidine 150mg/kg showed more histopathological changes compared to group two. Severe damage in the wall of the central vein, focal inflammatory cells infiltration near the central vein resulting in hemorrhage, expansion in sinusoid. Moreover, more severe necrotic foci in some regions and accumulation of high number of fibroblasts (Fig. 2-C). Table 1 show the measure of central vein an hepatocytes the measure of central vein is decreased with the high concentration but the hepatocytes be more small with the high concentration.

### Effect of Ranitidine on kidneys

In the control group the kidneys have normal bowman corpuscles glomerulus, and tubules (Fig. 3A). in group two where mice treated orally with 75mg /kg of Ranitidine, kidneys showed large space between glomerulus and bowman corpuscle, hemorrhage, necrosis in some region and

presence of casts in the tubules (Fig. 3 B). In group three, where mice treated orally with 150 mg /kg ranitidine, kidneys were severely affected compared with second group. There were rupturing and increased of hemorrhage in glomeruli and large space of the tissue, hyperplasia cells in tubules and cast (Fig 3C). Table 2 the measured of glumerula and tubules show the decrease of the glumerula in the second group (Group 1) and be in normal measure in third group (Group 2) ,tubules be in large size in the second group (Group 1) and be normal in third group (Group 2).

**Table 1. Show the measurement of central vein and hepatocytes.**

Groups	Label	Area	Mean	Std. Dev.
Control	Central vein	9065.156	201.747	68.53
Control	Hepatocyte	5892.351	166.209	18.22
Group1	Central vein	13500.5	218.803	11.406
Group1	Hepatocyte	5167.139	163.678	14.757
Group2	Central vein	16951.84	229.261	7.255
Group2	Hepatocyte	3716.714	157.935	12.389

The results corresponded with those of (Hemieda, et al., 2005) who employed Ranitidine administration in male rats at doses of 10, 30, and 50 mg/kg b.w. for three weeks. They indicated negative effects in rats given 10 and 30 mg/kg. Treatment with 50 mg/kg resulted in a significant rise in the activity of acid phosphatase in the liver and aspartate aminotransferase (AST) in the serum and liver, as well as a tendency for an elevation of serum alanine aminotransferase (ALT). There was also a significant decrease in serum activity of both amylase and alkaline phosphatase. Microscopic analysis of the same animals' liver tissue revealed a lack of certain hepatic cells, pyknotic nuclei, blood sinusoids expansion, binucleated cells, and lymphocyte infiltration.

*In vitro* and *In vivo*, there are significant correlation in ranitidine accumulation and ADME characteristics; oral ranitidine has a medium absorption. Microsomal enzymes catalyze hepatic metabolism, which plays a modest part in total clearance. (Bell, 1980).

**Kidney disorders** In humans, around 30% of the oral dose is excreted as unaltered drug in the urine, followed by modest components of metabolites N-oxide (about 4-6%), s-oxide (about 1-2%), dimethyl-ranitidine (about 1-2%), and furic acid analognes (1-2%) (Martin, 1982). As a result of its importance as a filtration organ, this medication has an effect on the kidney.

Oxidative deamination forms the furic acid analogues. It's likely that the formation of this metabolite, as proposed by oxidative deamination, will also result in the release of

dimethylamine (DMA), which might then have been used to make NDMA when exposed to nitrite. However, in a publication describing human metabolism data (Martin, 1981).

According to the report of (Galaxosmith, 2012) In individuals with renal impairment (creatinine clearance less than 50 ml/min), ranitidine accumulates in the bloodstream, leading in high plasma concentrations. In such patients, a daily oral zantac dose of 150mg is indicated, with a zantac injectable dose of 25 mg. In patients with renal impairment, however, ranitidine is eliminated through the kidney, resulting in higher drug plasma levels. In renal impairment, the dose should be increased as described above under dosage and administration.

**Conclusion**

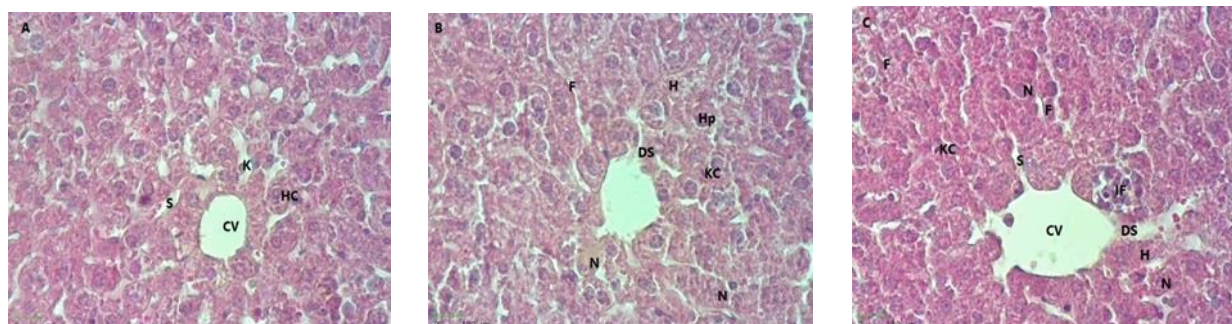
The ranitidine can cause hemorrhage and focal inflammation and desquamation in the central vein and an expansion in the sinusoid of the liver, also can cause hemorrhage and necrosis and the presence of cast in the tubules of kidneys, these increase with the increased doses.

**Ethics approval**

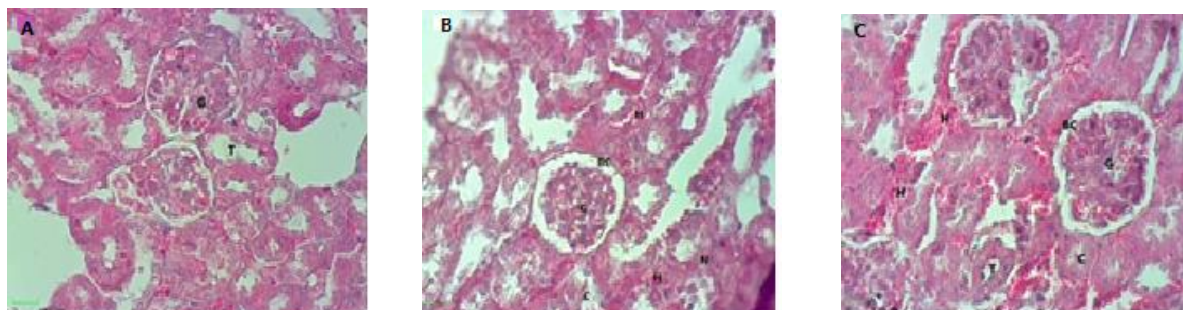
The laboratory animals were placed in special cages and left for a week to acclimatize, a special diet and sterile water were used, and the hours of light, darkness and the appropriate temperature were taken into account in the animal house of the collage of Veterinary / University of Tikrit, according to national and international guidelines for the care and use of laboratory animals, and approved by the animal care and use committee, collage of Veterinary / University of Tikrit, the command with the number 3372/14 in 13/1/2021.

**Table 2. The measurement of glumerula and tubules**

Groups	Label	Area	Mean	Std. Dev.
Control	Glumerul a	10556.7	165.414	29.683
Control	Tubules	7351.575	175.295	28.195
Group 1	Glumerul a	11247.17	135.359	41.11
Group 1	Tubules	5287.46	197.15	32.641
Group 2	Glumerul a	12879.82	150.196	33.356
Group 2	Tubules	5347.222	175.703	30.154



**Fig. 2.** Shows the effect of Ranitidine on mice liver. (A) The control group liver shows normal central vein (CV), normal hepatocytes (Hp), normal sinusoid (S), presence of Kupffer cells (KC). (B) Liver of mice treated with (75mg /kg /b.w.) Ranitidine showing desquamation of the wall of central vein (DS), necrosis (N), aggregation of fibroblasts (F), hemorrhage (H), normal hepatocytes (Hp), presence of Kupffer cells (KC). (C) Liver of mice treated with (150mg /kg /b.w.) Ranitidine showing damage in the wall of the central vein (DS), focal inflammatory cells infiltration near the central vein (IF) causing hemorrhage (H), expansion of sinusoids (S), necrosis in some regions (N) and aggregation of fibroblasts (F). (H&E) 400X



**Fig. 3.** Shows the effect of Ranitidine on mice kidneys. (A) Normal bowman corpuscles and glomerulus (G) and normal tubules (T). (B) Kidney of mice treated with (75mg /kg) Ranitidine showing large space between glomerulus (G) and bowman corpuscle (BC), hemorrhage (H), necrosis (N) cast in the tubules (C). (C) kidney of mice treated with (150mg /kg) Ranitidine showing rupturing in glomeruli (G), hemorrhage (H) and hyperplasia cells in tubules (T), and casts (C). (H&E) 400X.

**Conflict of Interest**

The author hereby declares no conflict of interest.

**Consent for publication**

The author declares that the work has consent for publication.

**Funding support**

The author declares that they have no funding support for this study.

**References**

(FDA) U.S. Food & Drug Administration (2019). Statment alerting patients and health care professionals of NDMA found in samples of ranitidine. FDA.

FDA. FDA updates and press announcements on NDMA in zantac (ranitidine). s.l : FDA, 2019.

Bell, J. A., Dallas, F. A., Jenner, W. N., & Martin, L. E. (1980). The metabolism of ranitidine in animals and man. *Soc. Trans.* 8(1) 93.

Fiona, J., King, Andrew, D., Searle, and Michael, W.U., Rquhart (2020). Ranitidine-Investigations into the root cause for the presence of N-Nitroso-N,N-dimethylamine in ranitidine hydrochloride drug substances and associated drug products. *American chemical Society.*2915-2926.

Galaxosmith, Kline Pte. Ltd. (2012) *Zantac is a trademark of Glaxosmith Kline group of compainies[Glaxosmith Klinelogo]*. Singapore.

Hemieda, F. A., Abdei-Hady, E. S. K., & Abou Elnga, M. A. (2005). Biochemical and histological studies on H2-receptor antagonist ranitidine-induced hepatotoxicity in rats. *Journal of experimental Biology.* 43(9):782-5.

King, F. J., Searle, A. D., & Urquhart, M. W. (2020). Ranitidine— investigations into the root cause for the presence of N-nitroso-N, N-dimethylamine in ranitidine hydrochloride drug substances and associated drug products. *Organic Process Research & Development*, 24(12), 2915-2926.

Llomas, Michelle (2021). *Zantac side effects.* florida : drugwatch.

Mahase, E. (2019). FDA recalls ranitidine medicines over potential cancer causing impurity.

Martin, L. E., Oxford, J., & Tanner, R. J. N. (1981). The use of on-line high-performance liquid chromatography-mass spectrometry for the

- identification of ranitidine and its metabolites in urine. *Xenobiotica*, 11(12), 831-840.
- Martin, L.E. and Oxford, J. and Tanner, R.J. (1982). Use of high- performance liquid chromatography mass spectrometry for the study of the metabolism of ranitidine in man. *Chromatography Journal*. 251(215).
- Suvarna, S. Kim and Bancroft, D. John (2019). *Bancofts theory and practice of histological techniques eight edition*.
- Wagner, J. A., & Colombo, J. M. (2020). Medicine and media: the ranitidine debate. *Clinical and Translational Science*, 13(4), 649-651.
- Woodcock, J. (2019). Statement alerting patients and health care professionals of NDMA found in samples of ranitidine. *Food and Drug Administration Statement. Director-Center for Drug Evaluation and Research*.

**How to cite this article**

Rashid, M.S. (2023). Histopathological effect of ranitidine (Zantac) on liver and kidneys in albino mice. *Science Archives*, Vol. 4(1), 34-38.  
<https://doi.org/10.47587/SA.2023.4106>

This work is licensed under a [Creative Commons Attribution 4.0 International License](https://creativecommons.org/licenses/by/4.0/)



**Publisher's Note:** MD International Publishing stays neutral about jurisdictional claims in published maps and institutional affiliations.