



The role of PET-CT-Scan in the initial staging of lymphoma

Rajaa Aziz Jabbar¹ and Riyadh Waheed AL. Esawi²

Department of Radiology, College of Medicine, University of Kufa, Iraq

Received: Oct 3, 2023/ Revised: Oct 29, 2023/Accepted: Oct 31, 2023

(✉) Corresponding Author: Rajaa Aziz Jabbar

Abstract

Fluorodeoxyglucose (FDG) positron emission's significance in lymphoma is currently growing. Previous research and literature have shown that FDG-PET has a higher diagnostic and staging accuracy than CT-scan for lymphoma. FDG-PET still has a drawback in the anatomical localization of the pathology. This study's goal is to evaluate the effectiveness of Positron Emission Tomography-Computed Tomography (PET-CT) for the initial staging of lymphoma. This prospective study involved 100 patients (39 females and 61 males) with an age rate from 3 to 69 years old (average 38 years). All patients were referred for tomography-computed tomography-computed tomography PET-CT- scan which proved by biopsy as Lymphoma for initial staging with Fluorine-18 fluorodeoxyglucose-Positron Emission Tomography-Computed Tomography Scan. The median patient age 38 (range 3 – 69) years, Males dominant represented 61%. Among the studied group, 60 patients had Hodgkin lymphoma (HL), and the remaining 40% with non-Hodgkin lymphoma (NHL) The mean SUV values were significantly increased with the advancing stage, (P. value 0.008). ROC analysis revealed that SUV was a good predictor of an advanced stage of malignancy, at an optimal cutoff point of ≥ 3 (SUV).

Keywords: FDG-PET, Lymphoma, PET-CT, Initial staging, Standardized Uptake Value.

Introduction

Lymphosarcoma, a malignancy originating from lymphocytes or lymphoblast, was formerly used to describe widespread types of the disease. Lymphoma may only affect the lymphatic system or it may develop as an extranodal illness. This, along with variable aggressiveness results in a diverse imaging appearance. Lymphomas can be categorized into two major groups: Hodgkin lymphoma (HL) and Non-Hodgkin lymphoma (NHL) which are a heterogeneous group of malignancies (Buchpiguel, 2011). Once lymphoma has been diagnosed by biopsy, the extent of the disease, or staging, is crucial for proper treatment planning and evaluating the prognosis (Kwee et al., 2008). The epidemiology 4% of all malignancies are lymphomas. 4Frampas E. Lymphomas: Fundamental information radiologists should understand. They are more prevalent in industrialized nations. Lymphoma, the third-most prevalent type of cancer in children, accounts for 10–15% of all cancers. Multimodality imaging of Hodgkin

disease and non-Hodgkin lymphomas in children (Diagn, 2013). Lymphoma can often present with B symptoms (fever, weight loss and night sweats). Lymphoma may manifest as an extra- or nodal illness. Classically High-grade NHL might present with complications related to mass effect, such as superior vena cava obstruction, cauda equina syndrome, etc. Hodgkin lymphoma and low-grade non-Hodgkin lymphoma (NHL) manifest as nodal disease. Each organ is susceptible to extranodal illness (Frampas, 2012). Lymphomas are a malignancy that arises from mature lymphocytes. Although the cause is uncertain but potential lymphoma due to genetic risk factors. viral infection, e.g. EBV, HTLV-1, HIV, HCV, HSV and HHV and bacterial infection, e.g. Helicobacter pylori, previous chemotherapy (especially alkalinizing agents) and pharmacological therapy, e.g. digoxin, prolonged immunosuppression, e.g. post-transplantation (Frampas, 2012). Currently, Lymphomas are classified according to the WHO classification of tumors of hematopoietic and lymphoid tissues in 2008 (Rubin, 2008). The main classification is into:

- 1-Hodgkin lymphoma (Hodgkin disease) (40%).
- 2- Non-Hodgkin lymphoma (60%).
- 3- mature B-cell lymphoma.
- 4- mature T-cell and NK-cell lymphoma.
- 5-post-transplant lymphoma proliferative disorders. The majority of lymphomas are B-cell (85%), the remainder being Tcell (15%).

This study's goal is to evaluate the effectiveness of Positron Emission Tomography-Computed Tomography (PET-CT) for the initial staging of lymphoma.

Materials and Method

Patients

One hundred individuals (39 females and 61 males) with ages ranging from 3 to 69 years old participated in this prospective study (average 38 years). For positron emission tomography-computed tomography, all patients were referred. For the first staging using Fluorine-18 fluorodeoxyglucose-positron emission tomography-computed tomography, a PET-CT scan was performed on a patient whose biopsy revealed they had lymphoma. Between December 2022 and December 2023, the radiology department at Al-Sader Medical City in Al-Najaf performed biopsies on our patients using either CT guidance or US-guided biopsy. The FDG PET-CT –CT Scan was performed at Amir AL-Momineen Specialty Hospital Oncology & Nuclear Medicine Center. The report of the FDG PET-CT scan was done by an experienced specialist in nuclear medicine. All patients have pathologically proven lymphomas without preference for age or gender. Any pregnant woman who has lymphoma owing to radiation exposure risk. Patients whose blood glucose levels at the time of the study were higher than 300 mg/dl to prevent FDG misinterpretation. Patients underwent only one PET-CT scan due to insufficient data.

Methods

By using a CT-guided biopsy, all patients had been diagnosed with lymphoma. The patients were assessed at a single facility utilizing a single protocol and PET-CT machines (GE Discovery IQ 3rings PET CT system) that imaged caudo-cranially from the vertex to the mid-thigh. Fluorine-18 fluorodeoxyglucose was injected intravenously (I.V.) and a PET scan was performed 2-3 minutes per bed after 65 minutes. Axial, coronal, and sagittal Positron emission tomography (PET) images were analyzed with and without attenuation correction and the Q-clear algorithm, and corresponding CT images were taken without oral or IV contrast studies using an Optima 540 16-slice CT. Positron emission tomography (PET) images were used to localize anatomical structures using low dose CT images. At the time of the 18F-FDG injection, each patient's fasting blood sugar level was measured.

All data are acquired with a combined PET/CT in-line systems. Positron emission tomography and multi-section sixteen helical computed tomography scanners are used in this unique device to capture co-registered computed tomography and Positron emission tomography images simultaneously.

Preparing the Patient

The patients must fast six hours prior to the assessment. The patient's body was freed of metallic objects, and a gown was dressed. To administer 18F-FDG, we inserted an IV cannula in the cubital fossa. Before the assessment and after receiving the 18F-FDG injection, the patients were advised to refrain from engaging in any intense activity to prevent the physiological absorption of fluorine-18 fluorodeoxyglucose by the muscles. The patient was told to empty his or her bladder before to the scan. Each patient's blood glucose levels are checked prior to FDG administration; they should be fewer than 200 mg/dl.

Patients with diabetes receiving insulin therapy shouldn't take their medication for at least 4 hours before receiving FDG. Ten diabetic patients with blood glucose levels greater than 200 mg/dl and fewer than 300 mg/dl participated in this investigation. These patients received one unit of normal saline instead of insulin, and their blood glucose levels were reassessed thereafter. In order to maintain normal blood glucose levels. Nine cases were delayed until the next day, while the study was completed the same day in five other cases where the blood glucose level was approved as being within the normal range but less than 180-200 mg/dl. In order to reduce brown fat activity, the patient's environment's temperature was reduced before the 18F-FDG injection.

Statistical Analysis

The Statistical Package for Social Sciences (SPSS) version 27 was used to enter and analyze the data. Depending on the type of variable, data are expressed as mean, standard deviation, frequencies, and percentages. Utilizing the Chi-Square Test to Compare Frequencies. Analysis of Variances (ANOVA) tests were used to compare the mean SUV values across several sites. Using various comparison techniques, pairwise comparisons of the SUV values of the original lesion, secondary lesion, and lymph node were made. Post-hoc analyses ANOVA was used to compare mean SUV values according to staging. Receiver Operating Characteristic (ROC) curve used to assess the validity of PET scan in the evaluation of staging of Lymphoma. The level of significance (P. value) is set at 0.05 below which the difference or correlation is considered significant.

Results and discussion

Demographic Characteristics

The study included 100 patients in all, with a mean age of 37.1 + 13.8 years. These results, along with other demographic details of the study group, demonstrate that men constituted

61% of the group as shown in (Table 1). 60 patients in the study group had Hodgkin lymphoma (HL), while the other 40% had non-Hodgkin lymphoma (NHL), (Fig. 1). The number of lesions or LAP discovered using the PET scan before and after therapy is shown in (Table 2); following treatment, the number of lesions/LAP was considerably decreased in all regions (P value = 0.008). However, there

were a total of 221 identified lesions/LAP before treatment, and there were only 176 after it, (Fig. 2). Comparison of the largest diameter of lesions/LAP detected by PET scan before and after treatment revealed a significant reduction in the size of lesion/LAP after treatment in all sites, (P. value<0.005) in all comparisons (Table 3).

Table 1. Demographic characteristics of the studied group (N=100)

Variable	No.	%
Mean age (SD) (year):	37.1 (13.8)	-
Mean weight (SD) (kg):	71.6 (23.1)	-
Gender	Male	61
	Female	39
Occupation	Employed	20
	Unemployed	70
	Student	10
Smokers	27	27.0
History of Hypertension	29	29.0
History of Diabetes Mellitus	10	10.0
Province of origin	Najaf	28
	Karbala	19
	Qadisiya	12
	Dhiqar	9
	Baghdad	7
	Others	25

SD: standard deviation of the mean
None of the patients had a history of COVID-19 infection

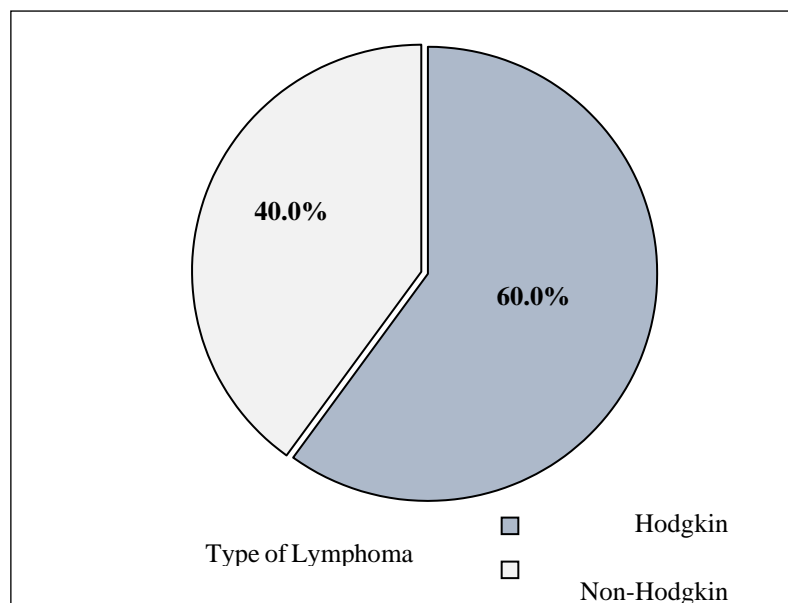


Fig. 1 Distribution of the studied group according to the type of lymphoma

Table 2. Number of lesions/LAP detected by PET scan before and after treatment PET

Site	Before treatment	After treatment
Head and Neck	8	5
	1	9
Chest	6	5
	2	1
Abdomen	5	5
	7	2
MSK	2	1
	1	4
Total	2	1
	2	7
	1	6
P. value = 0.008 significant		

Table 3. Comparison of the largest diameter of lesions/LAP detected by PET before and after treatment

Site of lesion	The largest diameter of the lesion (cm)				P. value
	Before treatment		After treatment		
	Mean	SD	Mean	SD	
Head and Neck	3.16	1.92	1.72	0.98	<0.001
Chest	3.03	1.85	2.35	1.10	0.001
Abdomen	3.55	1.09	2.97	1.19	0.004
MSK	7.75	2.11	5.69	2.48	0.009

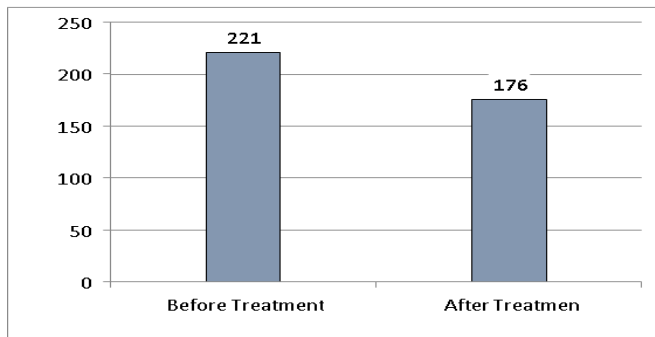


Fig. 2 Total number of lesions/LAP detected by PET scan before and after treatment

In order to evaluate the efficacy of treatment and subsequently predict relapse, an accurate radiographic assessment of treatment response in lymphoma patients is crucial. Recently, various studies have evaluated the predictive value and function of PET scans to determine how well they predict outcomes following therapy and the initial staging of lymphoma, which is essential for developing a treatment strategy and regimen (Cheson et al., 2014; Yoo et al., 2022). There is still a need for more accurate prognostic indicators since, despite significant advancements in the

treatment of lymphoma patients, many of them continue to relapse after treatment failure (Naguib et al., 2021; Gabus et al., 2021). In lymphoma patients, FDG-PET/CT has proven to be a standard imaging technique. However, a number of research and ideas regarding the techniques to gauge response and quantify target lesions were started (Naguib et al., 2021; Kim et al., 2018). In addition to determining tumor diameter in five or two lesions, it is advised to measure the standardized absorbance value (SUV) for each lesion. As a result, it is necessary to refine and confirm existing techniques for evaluating therapy response using FDG PET quantification. Since 2004, there has been mounting evidence in diagnostic imaging practice about the predictive utility of PET scans, and the SUV max is currently a widely utilized measure for various reasons due to its applicability and good measurement reproducibility. of measurements (Naguib et al., 2021; Freudenberg et al., 2004; Van et al., 2010).

Conclusion

PET-CT –Scan appears to have an important role and performance in the evaluation and staging of lymphoma.

PET-CT –Scan demonstrated high performance in the detection of nodal and extra nodal involvement.

Conflict of Interest

The author hereby declares no conflict of interest.

Consent for publication

The author declares that the work has consent for publication.

References

- Buchpiguel, C. A. (2011). Current status of PET/CT in the diagnosis and follow up of lymphomas. *Revista Brasileira De Hematologia E Hemoterapia*, 33(2), 140–147. <https://doi.org/10.5581/1516-8484.20110035>
- Cheson, B. D., Fisher, R. L., Barrington, S. F., Cavalli, F., Schwartz, L. H., Zucca, E., & Lister, T. A. (2014). Recommendations for Initial Evaluation, Staging, and Response Assessment of Hodgkin and Non-Hodgkin Lymphoma: The Lugano Classification. *Journal of Clinical Oncology*, 32(27), 3059–3067. <https://doi.org/10.1200/jco.2013.54.8800>
- Frapas, E. (2013). Lymphomas: Basic points that radiologists should know. *Diagnostic and Interventional Imaging*, 94(2), 131–144. <https://doi.org/10.1016/j.diii.2012.11.006>
- Freudenberg, L. S., Antoch, G., Schott, P., Beyer, T., Jentzen, W., Muller, S. P., Debatin, J. F. (2004). FDG-PET/CT in re-staging of patients with lymphoma. *European Journal of Nuclear Medicine and Molecular Imaging*, 31(3), 325–329.

- <https://doi.org/10.1007/s00259-003-1375-y>
- Gabus, R., Pavlovsky, A., Eleta, M., Skrypets, T., Kryachok, I., Novosad, O. & Chauvie, S. (2021). PET/CT Imaging of Lymphoma Outside the Western World. *Exon Publications*, 117-139. <https://doi.org/10.36255/exon-publications.lymphoma.2021.pet-imaging>
- Kim, H. J., Lee, R., Choi, H., Paeng, J. C., Cheon, G. J., Lee, D. S., Kang, K. W. (2018). Application of Quantitative Indexes of FDG PET to Treatment Response Evaluation in Indolent Lymphoma. *Nuclear Medicine and Molecular Imaging*, 52(5), 342–349. <https://doi.org/10.1007/s13139-018-0543-8>
- Kwee, T. C., Kwee, R. M., & Niewelstein, R. A. J. (2008). Imaging in staging of malignant lymphoma: a systematic review. *Blood*, 111(2), 504–516. <https://doi.org/10.1182/blood-2007-07-101899>
- Naguib, M. M., Botros, S. M., Louka, A. L., & Hussein, R. S. (2021). Role of PET/CT in initial evaluation of lymphoma patients. *Egyptian Journal of Radiology and Nuclear Medicine*, 52(1). <https://doi.org/10.1186/s43055-021-00670-3>
- Specialty Imaging: Postoperative SpineRossJeffrey Philadelphia, PA: Wolters Kluwer Lippincott Williams & Wilkins, 2012. ISBN 978-1-931884-89-1. Hardcover, \$249.00; pp 400. (2012). *Radiology*, 265(3), 694–694. <https://doi.org/10.1148/radiol.12124043>
- Yoo, K. H. (2022). Staging and response assessment of lymphoma: a brief review of the Lugano classification and the role of FDG-PET/CT. *Blood Research*, 57(S1), S75–S78. <https://doi.org/10.5045/br.2022.2022055>

How to cite this article

Jabbar, R. A., Al-Esawi, R. W. and Ghaith, R. F. (2023). The role of PET-CT-Scan in the initial staging of Lymphoma. *Science Archives*, Vol. 4(4), 286-290. <https://doi.org/10.47587/SA.2023.4407>

This work is licensed under a [Creative Commons Attribution 4.0 International License](https://creativecommons.org/licenses/by/4.0/)



Publisher's Note: The Journal stays neutral about jurisdictional claims in published maps and institutional affiliations.