



[Science Archives \(ISSN:2582-6697\)](https://doi.org/10.47587/SA.2026.7101)

Journal homepage: www.sciencearchives.org

<https://doi.org/10.47587/SA.2026.7101>

Research Article



Effect of Ethanolic Extract of *Chrysophyllum albidum* Pulp and Seed on Body Weight, Serum Electrolytes Concentration and Pancreatic Histology of Streptozotocin (STZ)-Induced Diabetic Rats

Saad Abdulkadir , Ameen Olanrewaju Adiru  and Ahmed Funsho Abdulhakim 

Biochemistry Unit, Science Laboratory, Technology Department, Institute of Applied Sciences, Kwara State Polytechnic, Ilorin Nigeria

✉ Corresponding Author: Abdul7465@gmail.com

Received: Feb 22, 2026/ Revised: March 16, 2026/Accepted: Mar 20, 2026

Abstract

Diabetes mellitus is a chronic metabolic disorder characterized by persistent hyperglycaemia, electrolyte imbalance, weight loss, and progressive pancreatic damage, largely due to insulin deficiency and oxidative stress. This study investigated the effect of ethanolic extracts of *Chrysophyllum albidum* pulp and seed on body weight, serum electrolyte concentrations, and pancreatic histology in streptozotocin (STZ)-induced diabetic rats. The study was carried out in the Biochemistry Laboratory, Kwara State Polytechnic, Nigeria, using a randomized controlled experimental design. Forty-two male Wistar rats (150–200 g) were randomly divided into seven groups: normal control, diabetic control, metformin-treated diabetic group (50 mg/kg), and diabetic groups treated with pulp (CAP) or seed (CAS) extracts at doses of 100 mg/kg and 200 mg/kg body weight for two weeks. Diabetes was induced by a single intraperitoneal injection of STZ (60 mg/kg body weight), and hyperglycaemia was confirmed after 72 hours. Body weight and fasting blood glucose levels were monitored, while serum bicarbonate, sodium, potassium, and chloride ion concentrations were determined using standard biochemical methods. Pancreatic tissues were examined histologically following haematoxylin and eosin staining. STZ-induced diabetes resulted in significant body weight loss, hyperglycaemia, and marked disturbances in serum electrolytes, characterized by elevated bicarbonate, sodium, potassium, and chloride levels. Histological examination of the pancreas in diabetic control rats revealed severe islet atrophy, reduced cellularity, and necrotic changes, confirming extensive β -cell damage. Treatment with metformin, CAP, and CAS significantly improved body weight, reduced fasting blood glucose levels, and normalized serum electrolyte concentrations toward values observed in non-diabetic controls. Notably, higher doses of CAP and CAS (200 mg/kg) produced more pronounced protective effects than lower doses. Histological findings in treated groups showed progressive restoration of pancreatic architecture, with increased islet size, improved cellularity, reduced necrosis, and near-normal morphology in high-dose extract-treated rats. In conclusion, ethanolic extracts of *Chrysophyllum albidum* pulp and seed exhibit significant antidiabetic, electrolyte-modulating, and pancreatic protective effects in STZ-induced diabetic rats. These effects may be attributed to the antioxidant and insulin-mimetic properties of bioactive phytochemicals present in the plant. The findings support the potential therapeutic use of *Chrysophyllum albidum* in the management of diabetes mellitus and its associated metabolic complications.

Keywords: *Chrysophyllum albidum* Body weight, Electrolytes concentration Pancreas, Streptozotocin (STZ), Diabetes, and Rats

1. Introduction

Diabetes mellitus is a chronic metabolic disorder characterized by persistent hyperglycemia resulting from defects in insulin secretion, insulin action, or both, leading to disturbances in carbohydrate, lipid, and protein metabolism (International Diabetes Federation, 2023; Chen *et al.*, 2023). The global burden of diabetes continues to rise rapidly, particularly in low- and middle-income countries, where limited healthcare access and lifestyle transitions worsen disease outcomes (IDF, 2023; Okeke *et al.*, 2024). Persistent hyperglycemia promotes oxidative stress, inflammation, and metabolic dysregulation, which contribute to long-term complications affecting multiple organs, including the pancreas, kidneys, cardiovascular system, and nervous system (Zhang *et al.*, 2024; Alam *et al.*, 2024). As a result, diabetes is frequently accompanied by weight loss, electrolyte imbalance, and structural damage to pancreatic tissue, all of which worsen disease prognosis and increase mortality risk (Kumar *et al.*, 2023; Bello *et al.*, 2024).

Streptozotocin (STZ) is widely employed to induce experimental diabetes in laboratory animals due to its selective toxicity toward pancreatic β -cells (Rahman *et al.*, 2023; Alam *et al.*, 2024). STZ enters β -cells via the glucose transporter GLUT2, causing DNA alkylation, excessive generation of reactive oxygen species, and mitochondrial dysfunction, ultimately leading to β -cell necrosis and insulin deficiency (Rahman *et al.*, 2023; Ogunyemi *et al.*, 2024). The resulting insulin insufficiency disrupts glucose uptake and utilization, leading to enhanced proteolysis and lipolysis, muscle wasting, dehydration, and progressive body weight loss (Kumar *et al.*, 2023; Adeyemi *et al.*, 2023). Consequently, changes in body weight serve as a reliable marker of metabolic impairment and therapeutic efficacy in STZ-induced diabetic models (Alam *et al.*, 2024; Bello *et al.*, 2024).

In addition to alterations in body weight, diabetes mellitus is commonly associated with significant disturbances in serum electrolyte concentrations, including sodium, potassium, chloride, and bicarbonate ions (Chen *et al.*, 2023; Verma *et al.*, 2024). Hyperglycemia-induced osmotic diuresis increases urinary electrolyte loss, while insulin deficiency alters the activity of sodium–potassium ATPase, impairing intracellular potassium uptake and disrupting sodium and chloride balance (Zhang *et al.*, 2024; Musa *et al.*, 2024). These abnormalities may result in hyponatremia, hyperkalemia, altered chloride levels, and bicarbonate imbalance, predisposing diabetic individuals to cardiovascular dysfunction, neuromuscular complications, and acid–base disorders (Chen *et al.*, 2023; Verma *et al.*, 2024). Restoration of electrolyte homeostasis is therefore an important therapeutic goal in diabetes management, alongside glycemic control (Adeyemi *et al.*, 2023; Musa *et al.*, 2024).

The pancreas plays a central role in glucose homeostasis, and histopathological alterations in pancreatic tissue are hallmark features of diabetes mellitus (Rahman *et al.*, 2023; Bello *et al.*, 2024). STZ-induced diabetes is characterized by reduced size and number of islets of Langerhans, decreased β -cell mass, cellular necrosis, vacuolization, and inflammatory infiltration (Rahman *et al.*, 2023; Ogunyemi *et al.*, 2024). These structural changes directly impair insulin synthesis and secretion, perpetuating hyperglycemia and metabolic instability (Alam *et al.*, 2024; Bello *et al.*, 2024). Histological assessment of pancreatic tissue therefore provides critical insight into disease severity and the protective or regenerative potential of therapeutic agents, particularly those with antioxidant and cytoprotective properties capable of mitigating oxidative stress-induced β -cell damage (Rahman *et al.*, 2023; Okeke *et al.*, 2024).

Medicinal plants have gained increasing attention as alternative or complementary therapies for diabetes

due to their affordability, availability, and rich bioactive composition (Okeke et al., 2024; Ogunyemi et al., 2024). *Chrysophyllum albidum* (African star apple) is a tropical plant widely consumed in West Africa and traditionally used for the management of various ailments (Adebayo et al., 2023; Lawal et al., 2024). The pulp and seed of *C. albidum* are rich in flavonoids, phenolic compounds, saponins, tannins, alkaloids, and vitamins, which exhibit antioxidant, anti-inflammatory, and antidiabetic activities (Adebayo et al., 2023; Lawal et al., 2024). Previous studies have reported the hypoglycemic, hypolipidemic, and antioxidant effects of *C. albidum* pulp and seed extracts in diabetic models (Ogunyemi et al., 2024; Adeyemi et al., 2023), yet limited data exist on their comparative effect on body weight regulation, serum electrolyte balance, and pancreatic histological integrity. Therefore, this study investigated the effect of ethanolic extract of *Chrysophyllum albidum* pulp and seed on body weight, serum electrolyte concentrations, and histological changes of the pancreas in streptozotocin-induced diabetic rats, with the aim of providing scientific evidence for its therapeutic potential in diabetes management.

Materials and Method

Study Area

This study was carried out in Biochemistry Laboratory, Kwara State Polytechnic, Kwara State, Nigeria. This experimental study used a randomized control trial design involving streptozotocin-induced diabetic rats. The study was conducted in accordance with the guidelines for the care and use of laboratory animals.

Ethical Approval

The study was carried out after ethical approval was obtained from University of Ilorin ethical review committee, Ilorin, Kwara State, Nigeria.

Experimental Animals

Male Wistar rats weighing between 150-200 g were purchased and used in for this study. The animals were kept in an animal house under standard laboratory conditions. The conditions included 12 hours of light and dark cycles at a temperature of $25\pm 2^{\circ}\text{C}$, as well as unlimited access to standard pellet food and water. The animal housing facility maintained controlled environmental conditions: a consistent temperature of $22\pm 2^{\circ}\text{C}$, a relative humidity of 50–60, and a strict 12-hour light/dark cycle (lights on at 07:00 AM, off at 07:00 PM). Throughout the entire experimental duration, rats will have *ad libitum* access to a standard laboratory pellet diet and fresh distilled water, which will be replenished daily. Daily observations included monitoring for any signs of distress, changes in appetite, water intake, body weight, and general activity.

Experimental Design

A total of 42 rats were randomly allocated into the following seven distinct experimental groups. Randomization was performed using a random number generator to minimize selection bias and ensure group comparability at baseline.

Group 1: Normal Control (ND + water): Non-diabetic (ND) rats received an equivalent volume of distilled water orally daily via gavage. This group served as a baseline for normal physiological parameters.

Group 2: Diabetic Control (Negative Control) (D control): This group contained STZ-induced diabetic rats that received an equivalent volume of distilled water orally daily via gavage. This group represents untreated diabetic rats and demonstrates the progression of hyperglycemia without intervention.

Group 3: Standard Drug Control (Positive Control) (D + 50 mg/kg body weight metformin): This group contains STZ-induced diabetic rats which received 50

mg/kg body weight of metformin hydrochloride orally daily.

Group 4: *Chrysophyllum albidum* Pulp (D + 100 mg/kg body weight CAP): STZ-induced diabetic rats receiving a low dose of 100 mg/kg body weight of the *C. albidum* pulp extract orally daily.

Group 5: *Chrysophyllum albidum* Pulp (D + 200 mg/kg body weight CAP): STZ-induced diabetic rats receiving a high dose of 200 mg/kg body weight of the *C. albidum* pulp extract orally daily.

Group 6: *Chrysophyllum albidum* Seed (D + 100 mg/kg body weight CAS): STZ-induced diabetic rats receiving a low dose of 100 mg/kg body weight of the *C. albidum* seed extract orally daily.

Group 7: *Chrysophyllum albidum* Seed (D + 200 mg/kg body weight CAS): STZ-induced diabetic rats receiving a high dose of 200 mg/kg body weight of the *C. albidum* seed extract orally daily.

Note: CAP = (*Chrysophyllum albidum* Pulp), and CAS= (*Chrysophyllum albidum* Seed)

Collection of *Chrysophyllum albidum* Pulp and Seed

Fresh pulps of *Chrysophyllum albidum* were collected, authenticated and after which, sun-dried. The collected plant material underwent rigorous botanical identification and authentication by a qualified plant taxonomist or botanist. This crucial step confirmed the species and prevents misidentification.

Pulp Separation and Preparation

Upon collection, the fruits were thoroughly washed under running tap water to remove any dirt, debris, or surface contaminants. The outer pericarp was carefully peeled, and the fleshy pulp was manually separated from the seeds. To preserve the integrity of thermolabile bioactive compounds, the pulp was thinly

spread on clean trays and air-dried at ambient room temperature (25–30°C) in a shaded, well-ventilated area until the pulp reached a constant weight, indicating complete moisture removal. The dried pulp was then be pulverized into a fine, homogeneous powder using a sterile mechanical grinder or blender. The resulting powder was sieved through a fine mesh (e.g., 60-mesh size) to ensure uniform particle size which aided in efficient extraction.

Seed Separation and Preparation

The seeds, separated from the pulp, was also be thoroughly washed to remove any adhering pulp residues. They were then be air-dried under similar conditions as the pulp. Once dried, the hard outer shell of each seed was carefully cracked and removed to obtain the inner kernel. These kernels were then pulverized into a fine powder using a heavy-duty mechanical grinder, followed by sieving to obtain a fine, uniform powder.

Both the powdered *Chrysophyllum albidum* pulp (CAP) and seed (CAS) materials were immediately transferred into opaque, airtight containers (dark glass bottles) and stored in a cold room or freezer at 4°C until the extraction process to prevent degradation, moisture absorption, and microbial contamination.

Preparation of Pulp and Seed Extract

400g of the meshed pulp was macerated in 2 Litres of ethanol for 72hrs. The mixture was sieved with muslin cloth, and filtered with No.1 whatman filter paper. The extract was concentrated using rotary evaporator at reduced temperature of 20 °C and 150 pressure. It was further dried using water bath at 400°C. The extract was stored in the fridge until required for use. The extract was then concentrated under reduced pressure and stored at 25°C until it was required for use. The same procedure was done for *Chrysophyllum albidum* seeds in order to obtain the seed extract.

Induction of Diabetes

Diabetes was induced in the experimental rats by a single intraperitoneal (IP) injection of streptozotocin (STZ). STZ is a glucose analogue that selectively targets and destroys pancreatic β -cells, leading to insulin deficiency and subsequent hyperglycemia. To ensure its stability and efficacy, STZ was freshly dissolved in cold 0.1 M citrate buffer (pH 4.5) immediately prior to administration. The chosen dose of 60 mg/kg body weight is a standard dose known to reliably induce stable and severe hyperglycemia in rats.

Confirmation of Diabetes and Treatment of Experimental Animals

After a 72-hour post-STZ injection period, which allowed for the full diabetogenic effect to manifest, fasting blood glucose (FBG) levels were measured from blood samples collected from the tail vein of each rat. Only rats exhibiting consistent FBG levels ≥ 200 mg/dL (or 11.1 mmol/L) were considered successfully diabetic and included in the study. This threshold ensured a clear distinction between diabetic and non-diabetic animals and a uniform baseline of hyperglycemia across the treatment groups. After induction and confirmation of diabetes, the rats were treated daily for two (2) weeks with *Chrysophyllum albidum* pulp and seed extract and the standard drug.

Biochemical and Histological Analysis

Biochemical Analysis

Determination of Serum Bicarbonate Ion Concentration of Streptozotocin (STZ)-Induced Diabetic Rats Treated with Ethanolic Extract of *Chrysophyllum albidum* Pulp

Serum bicarbonate ion concentration was determined as described by Tietz (1995). 1ml of working reagent was added to a clean set of tubes labeled sample, standard and blank. The sample, standard and blank

was made by adding 0.5 ml of serum, standard solution and distilled water respectively. The mixture was incubated at 37 °C for 5 minutes and the absorbance of the sample and standard read at 340 nm against reagent blank.

Determination of Serum Sodium Ion Concentration of Streptozotocin (STZ)-Induced Diabetic Rats Treated with Ethanolic Extract of *Chrysophyllum albidum* Pulp

Serum sodium ion concentration was determined as described by Tietz (1995). Procedure: Appropriately diluted sample (100 μ l) was added to 5 ml of working standard. The blank was set up by substituting the sample with the distilled water. The preparation was thoroughly mixed. The galvanometer was put on and the sodium light filter inserted. The gas and air supply was attuned to obtain discrete blue flame. The blank was used to zero the galvanometer and the sample readings were taken at 590 nm.

Determination of Serum Potassium Ion Concentration of Streptozotocin (STZ)-Induced Diabetic Rats Treated with Ethanolic Extract of *Chrysophyllum albidum* Pulp

Serum potassium ion concentration was determined as described by Tietz (1995). Appropriately diluted sample (100 μ l) was added to 2500 μ l of working standard. The blank was set up by substituting the sample with the distilled water. The preparation was thoroughly mixed. The galvanometer was switched on and the potassium light filter implanted. The gas and air source was attuned to obtain discrete blue flame. The blank was used to zero the galvanometer and adjusted to 4.4 with the working standard. The absorbance of the sample was read against the blank at 770 nm.

Determination of Serum Chloride Ion Concentration of Streptozotocin (STZ)-Induced Diabetic Rats Treated with Ethanolic Extract of *Chrysophyllum albidum* Pulp

Serum chloride ion concentration was determined as described by Tietz (1995). Appropriately diluted sample (100 μ l) was added to a clean tube. Blank and standard were prepared by substituting the sample with 100 μ l of distilled water and standard respectively. Working reagent (1 ml) was added to the tubes and the mixture incubated at 37°C for 45 minutes. The absorbance of the test samples and standard were read at 436 nm against reagent blank.

Histological Analysis

All animals were sacrificed for histological examination. The pancreas was removed and fixed in a 10% buffered neutral formalin solution (21). Small samples were taken from each organ and were treated with traditional histological methods, including dehydration in ethyl alcohol, clearing in xylol, and embedding in hot paraffin wax. The wax blocks were sectioned (5 μ m) using a microtome, and the slides were stained with ordinary Harris hematoxylin and eosin (aqueous). The histopathological samples were examined using an optical microscope with two lenses: (OLYMPUS, Japan) and photographed using an OMAX 18MP LAPAN camera (China)

Statistical Analysis

The Statistical Package for Social Sciences (SPSS, version 25) was used for statistical analysis. The experimental data were presented as mean values with their standard deviation (mean \pm SD) and analyzed using a one-way analysis of variance (ANOVA). A probability level of $P \leq 0.05$ was considered statistically significant.

Results

Effect of Ethanolic Extract of *Chrysophyllum albidum* Pulp and Seed on Body Weight of STZ-Induced Diabetic Rats

Table 1 and Figure 1 below show the result of the effect of ethanolic extract of *Chrysophyllum albidum* pulp (CAP) and seed (CAS) on the body weight of streptozotocin (STZ)-induced diabetic rats over a 13-day period. In the normal (non-diabetic) control group, rats exhibited a stable increase in body weight from 177.00 \pm 2.01 g on day 1 to 185.50 \pm 4.00 g by day 13. In contrast, the diabetic control group showed a progressive and significant weight reduction from 197.00 \pm 10.74 g to 166.00 \pm 7.07 g over the same period.

The group treated with metformin, a standard antidiabetic drug, also experienced a decrease in body weight from 186.66 \pm 5.68 g to 166.00 \pm 7.00 g. Among the groups treated with *Chrysophyllum albidum* extracts, notable differences emerged based on the type of extract (pulp or seed) and dosage. The diabetic group administered 100 mg/kg CAP experienced a decline in body weight from 173.50 \pm 7.35 g to 151.00 \pm 7.59 g by day 13, indicating some protective effect, though not sufficient to reverse the weight loss trend. However, the group that received 200 mg/kg CAP exhibited an initial increase in weight from 178.67 \pm 6.07 g to 185.33 \pm 6.22 g on day 7, followed by a slight reduction to 176.00 \pm 7.08 g on day 13.

For the groups treated with the CAS extract, the 100 mg/kg dose resulted in a marked weight loss from 192.17 \pm 4.53 g to 152.00 \pm 2.73 g, the steepest decline among all groups. However, the group treated with 200 mg/kg CAS maintained relatively stable body weights across the study duration, starting at 173.67 \pm 0.91 g and ending at 171.17 \pm 3.57 g. Comparatively, the 200 mg/kg CAP and CAS treatments were the most effective in preserving body

weight in diabetic rats, showing similar performance than the diabetic control or the metformin group. to the normal group and significantly better outcomes

Table 1. Effect of Ethanolic Extract of *Chrysophyllum albidum* pulp and seed on body weight of STZ-induced diabetic rats

Group	day 1	day 7	day 13
ND + water	177.00 ± 2.01	178.33 ± 2.24	185.50 ± 4.00
D control	197.00 ± 10.74	190.50 ± 12.87	166.00 ± 7.07
D + 50mg/kg body weight metformin	186.66 ± 5.68	183.43 ± 16.62	166.00 ± 7.00
D + 100mg/kg body weight CAP	173.50 ± 7.35	171.50 ± 7.06	151.00 ± 7.59
D + 200mg/kg body weight CAP	178.67 ± 6.07	185.33 ± 6.22	176.00 ± 7.08
D + 100mg/kg body weight CAS	192.17 ± 453	190.83 ± 3.56	152.00 ± 2.73
D + 200mg/kg body weight CAS	173.67 ± 0.91	173.83 ± 1'.31	171.17 ± 3.57

*Values are expressed as Means ± SEM of three replicates

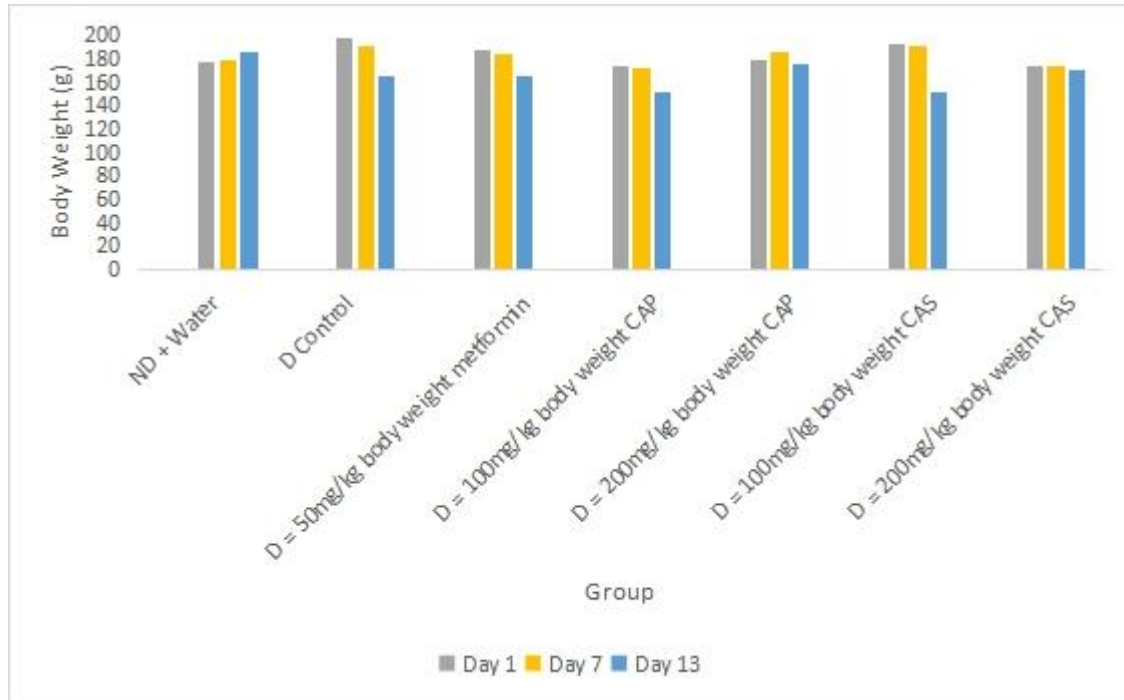


Figure 1. Effect of ethanolic extract of *Chrysophyllum albidum* pulp and seed on body weight of STZ-induced diabetic rats *Values are expressed as Means \pm SEM of three replicates

Effect of Ethanolic Extract of *Chrysophyllum albidum* Pulp and Seed on Serum Bicarbonate Concentration of Streptozotocin (STZ)-Induced Diabetic Rats

Figure 2 below shows the result of the effect of ethanolic extract of *Chrysophyllum albidum* on serum bicarbonate concentration of streptozotocin (STZ)-induced diabetic rats The "D control" group exhibited

significantly elevated bicarbonate. However, the "ND + water" group, representing a normal state, showed much lower bicarbonate levels. Importantly, all tested therapeutic interventions; metformin, CAP, and CAS, at different dosages effectively reduced the abnormally high bicarbonate concentrations observed in the disease model. These treatments successfully normalized bicarbonate levels, bringing them closer to those found in the healthy control group.

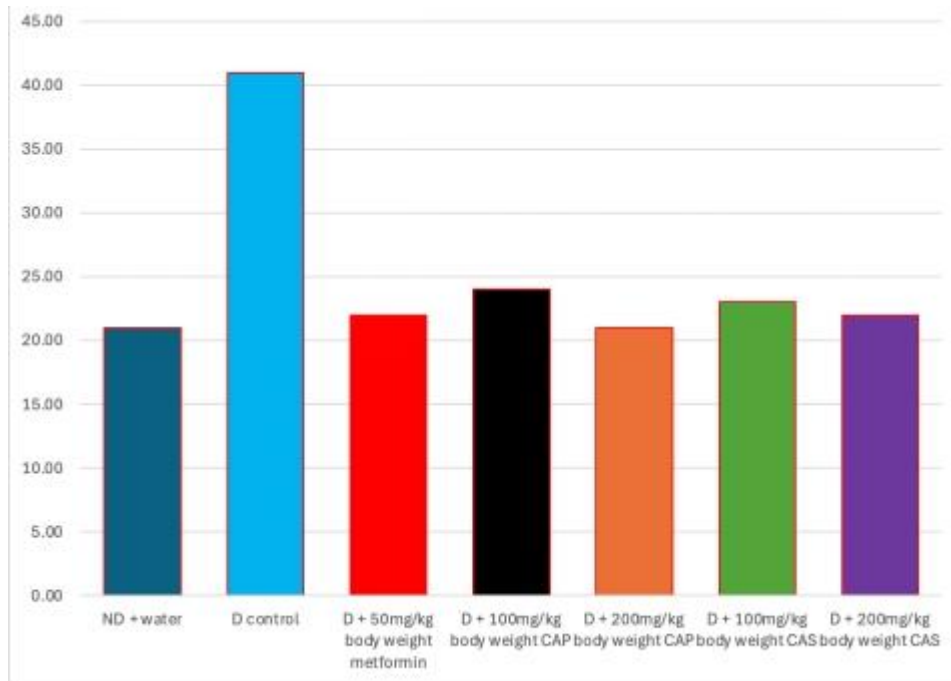


Figure 2. Serum bicarbonate concentration of STZ-induced diabetic rats treated with ethanolic extract of *Chrysophyllum albidum* pulp and seed *Values are expressed as Means \pm SEM of three replicates

Effect of Ethanolic Extract of *Chrysophyllum albidum* Pulp and Seed on Serum Sodium Ion Concentration of Streptozotocin (STZ)-Induced Diabetic Rats

Figure 3 shows the result of serum sodium ion concentration of STZ-induced diabetic rats treated with ethanolic extract of *Chrysophyllum albidum* pulp. The "D control" group showed the highest sodium concentration, peaking at approximately 67.0 mEq/L, indicating elevated levels in the disease state. In contrast, the "ND + water" group, representing a

healthy control, shows a lower serum sodium level of about 58.0 mEq/L. All treatment groups, including metformin, CAP, and CAS at different dosages, demonstrate a reduction in these elevated sodium levels compared to the "D control." The treated groups generally fall within a range of approximately 54.0 mEq/L to 59.0 mEq/L, bringing the sodium levels closer to, or even slightly below, the normal control group. This suggests that the disease model leads to hypernatremia, and all tested treatments effectively mitigate this increase, helping to restore serum sodium balance.

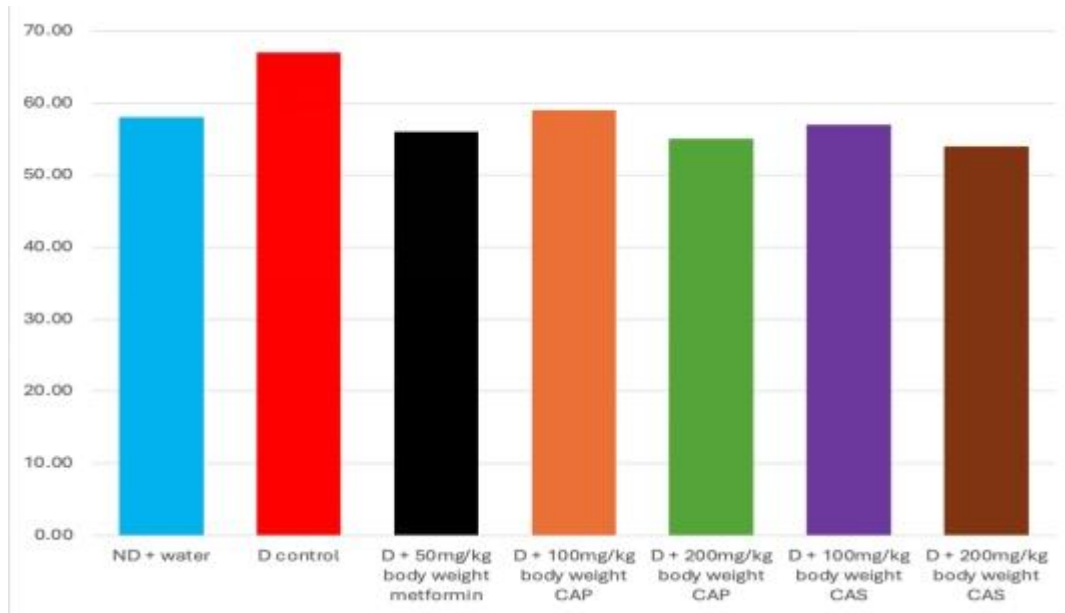


Figure 3. Serum sodium ion concentration of STZ-induced diabetic rats treated with ethanolic extract of *Chrysophyllum albidum* pulp and seed *Values are expressed as Means \pm SEM of three replicates

Effect of Ethanolic Extract of *Chrysophyllum albidum* Pulp and Seed on Serum Potassium Ion Concentration of Streptozotocin (STZ)-Induced Diabetic Rats

Figure 4 shows the result of serum potassium ion concentration of STZ-induced diabetic rats treated with ethanolic extract of *Chrysophyllum albidum* pulp. All tested treatments (metformin, CAP, and CAS at various doses) appear to effectively reduce these

elevated potassium levels, bringing them closer to the range observed in the normal control group. The 200mg/kg CAP dose seems to be the most effective in reducing potassium levels to below the normal control, while other treatments also show a beneficial effect in normalizing the elevated potassium. The result also showed that the group represented by "D control" showed significant elevation in potassium levels, possibly indicating an electrolyte imbalance.

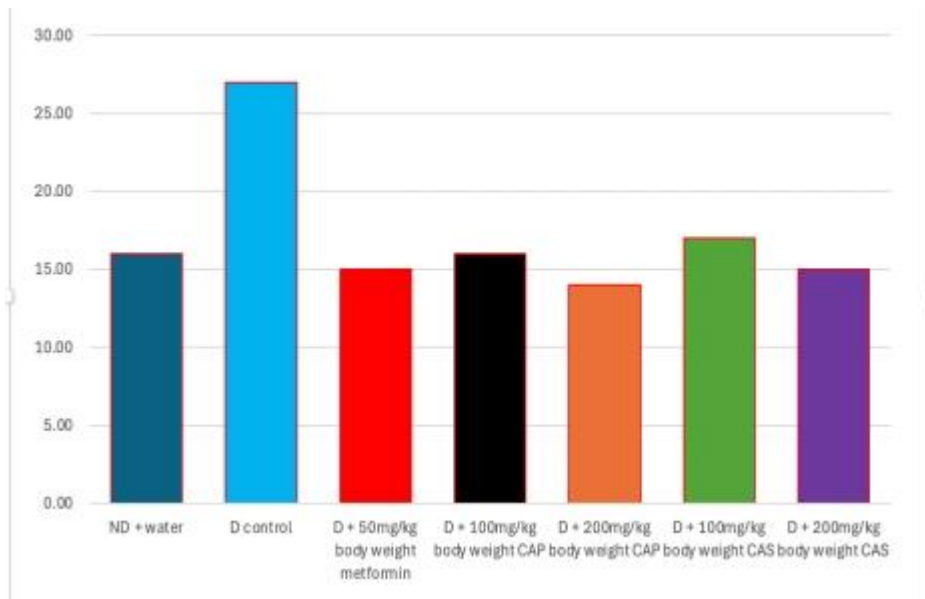


Figure 4. Serum potassium ion concentration of STZ-induced diabetic rats treated with ethanolic extract of *Chrysophyllum albidum* pulp and seed *Values are expressed as Means \pm SEM of three replicates

Effect of Ethanolic Extract of *Chrysophyllum albidum* on Serum Chloride Ion Concentration of Streptozotocin (STZ)-Induced Diabetic Rats

Figure 5 shows the result of serum chloride ion concentration of STZ-induced diabetic rats treated with ethanolic extract of *Chrysophyllum albidum* pulp. The "D control" group exhibits the highest chloride concentration, notably elevated at around 63.0 mEq/L. Conversely, the "ND + water" group, representing the healthy control, shows a lower chloride level of approximately 56.0 mEq/L. Among the treatment groups, "D + 50mg/kg metformin" shows the lowest

chloride level, around 39.0 mEq/L. The CAP-treated groups (100mg/kg and 200mg/kg) have chloride levels of approximately 48.0 mEq/L and 42.0 mEq/L, respectively. The CAS-treated groups show varying responses, with "D + 100mg/kg CAS" at around 49.0 and "D + 200mg/kg CAS" at about 36.0 mEq/L, which is the lowest among all treatment groups. Overall, the disease model appears to increase chloride levels, and while all treatments reduce these elevated levels, the 200mg/kg CAS dose seems to be the most effective in reducing chloride ion concentration.

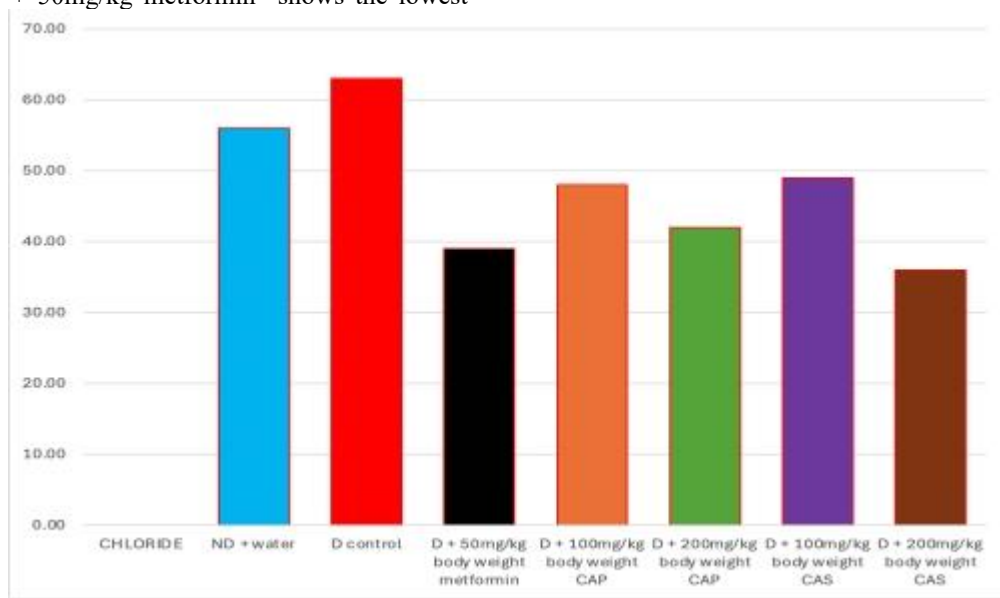


Figure 5. Serum chloride ion concentration of STZ-induced diabetic rats treated with ethanolic extract of *Chrysophyllum albidum* pulp and seed *Values are expressed as Means ± SEM of three replicates

Histological Assessment of the Effect of Ethanolic Extract of *Chrysophyllum albidum* Pulp and Seed on Pancreas of Streptozotocin (STZ)-Induced Diabetic Rats

The histological examination of pancreatic tissues across the experimental groups reveals progressive structural alterations associated with streptozotocin (STZ)-induced diabetes, as well as varying degrees of histological restoration following treatment. The observed changes primarily involve the islets of Langerhans, which are the major endocrine components of the pancreas responsible for insulin secretion, alongside the exocrine glands and supporting microanatomical structures.

In SA 1, the pancreatic section shows a marked reduction in the number and size of islets of Langerhans, most of which appear atrophic with reduced cellularity. This finding is characteristic of STZ-induced pancreatic injury, where β -cell destruction results in islet shrinkage and cellular depletion. The atrophic appearance reflects impaired insulin production and endocrine dysfunction. Despite the severe islet damage, the exophytic glands, ducts, and blood vessels retain moderately normal morphology, indicating that STZ selectively targets the endocrine pancreas while largely sparing the exocrine components at this stage.

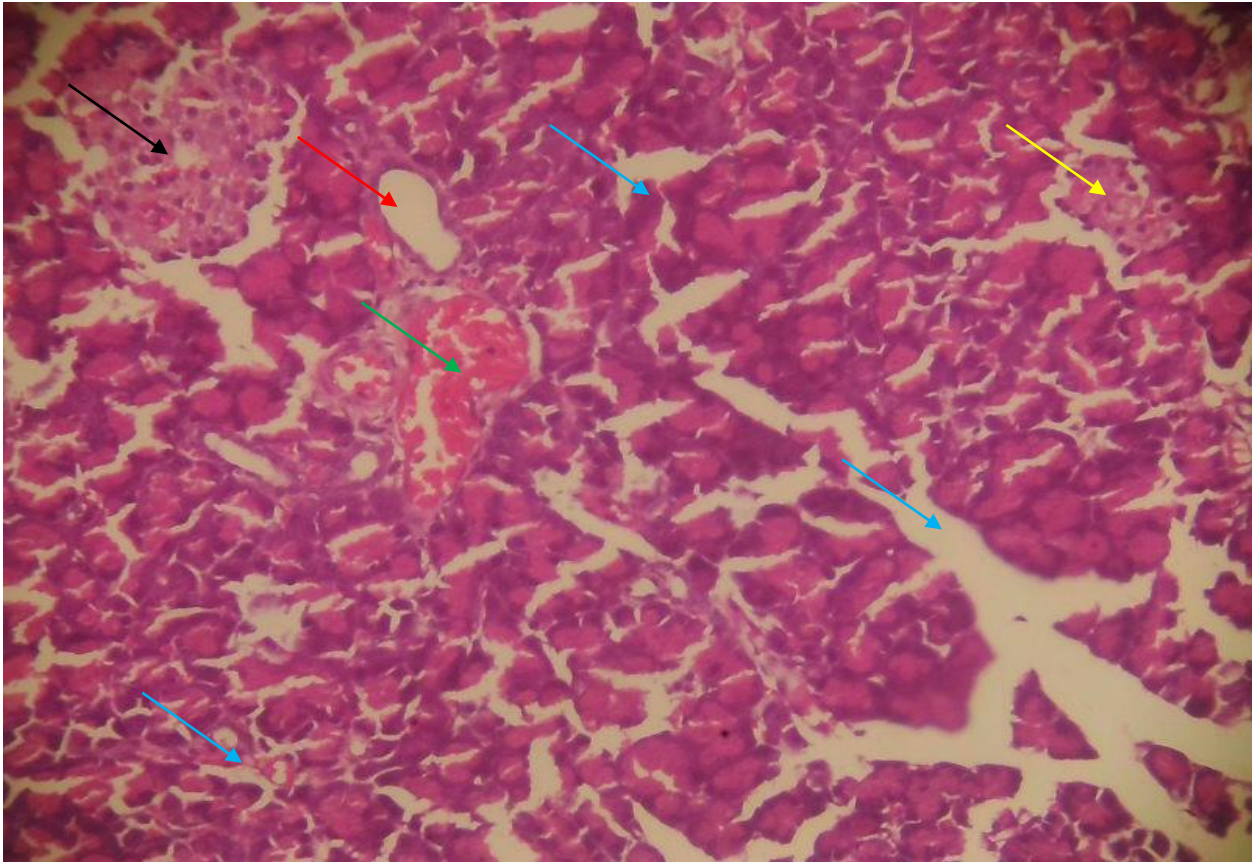
SA 2 demonstrates extensive necrotic changes within the exophytic glands, suggesting a more severe pancreatic insult. However, the islets of Langerhans exhibit moderate diameters with increased cellularity, implying partial regeneration or compensatory hyperplasia of surviving endocrine cells. This paradoxical observation may reflect an adaptive response to hyperglycaemia, where residual β -cells undergo proliferation to compensate for insulin deficiency. Nonetheless, the presence of necrosis indicates ongoing oxidative stress and inflammatory damage within the pancreatic tissue.

In SA 3, the pancreatic architecture shows notable improvement. The islets of Langerhans appear enlarged with wider diameters and more active cellularity, suggesting enhanced endocrine recovery. The exophytic glands, ducts, and blood vessels maintain relatively preserved structures within moderate limits. This histological pattern is indicative of pancreatic protection or regeneration, likely mediated by therapeutic intervention that attenuates oxidative damage and promotes cellular survival and proliferation.

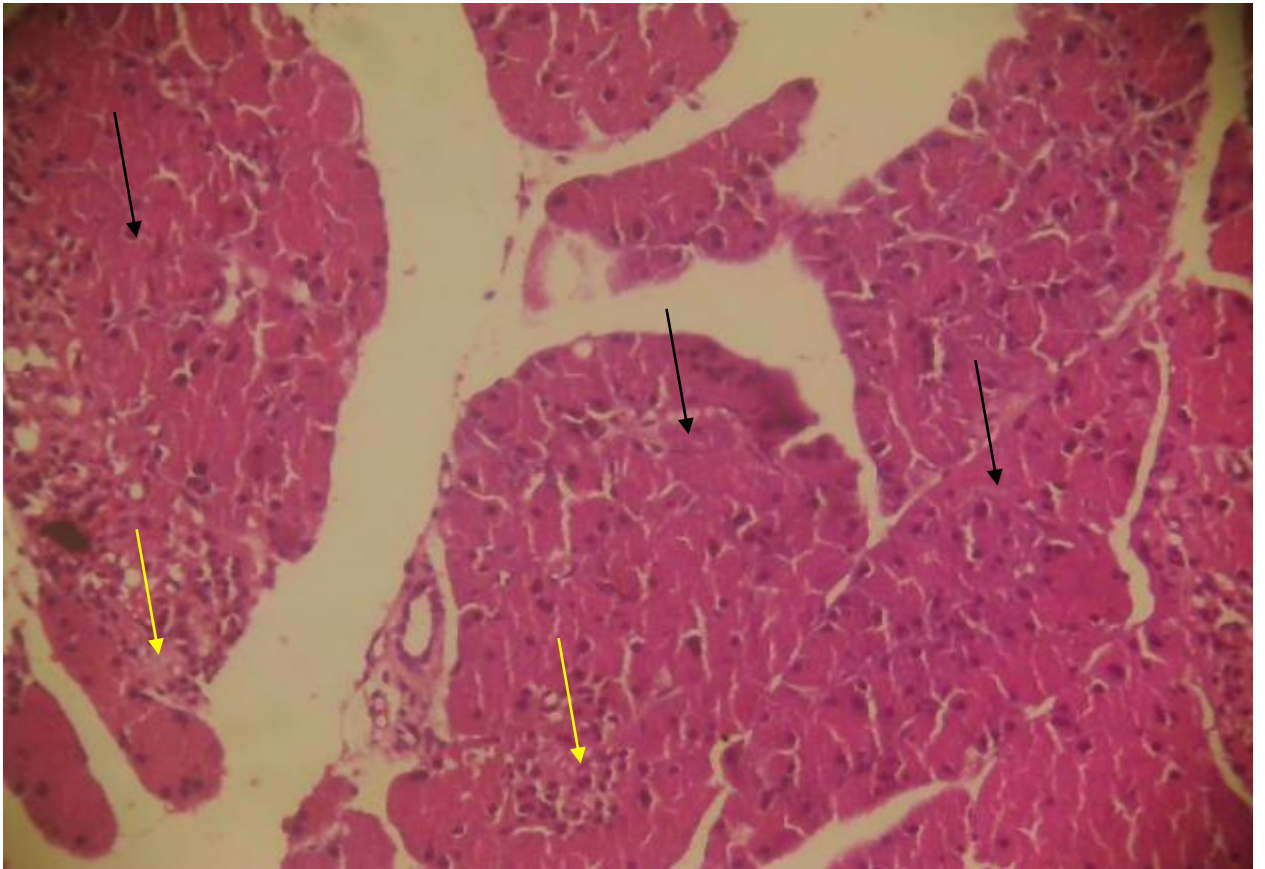
SA 4 reveals islets of Langerhans with varying diameters and cellularity, accompanied by the presence of cytoplasmic vacuoles and reactive changes. The vacuolation suggests residual cellular stress or metabolic derangement, while the reactivity points to ongoing repair and remodeling processes. Although the exophytic glands remain within moderate limits, the heterogeneous appearance of the islets indicates partial recovery rather than complete restoration of endocrine function.

In SA 5, the pancreatic tissue exhibits a moderate number of islets of Langerhans with improved cellularity and reactivity. The islets appear more organized and structurally defined compared to earlier sections, reflecting further recovery of endocrine architecture. The exophytic glands and associated microanatomical structures also appear within moderate limits, supporting the notion of overall pancreatic stabilization and reduced pathological insult.

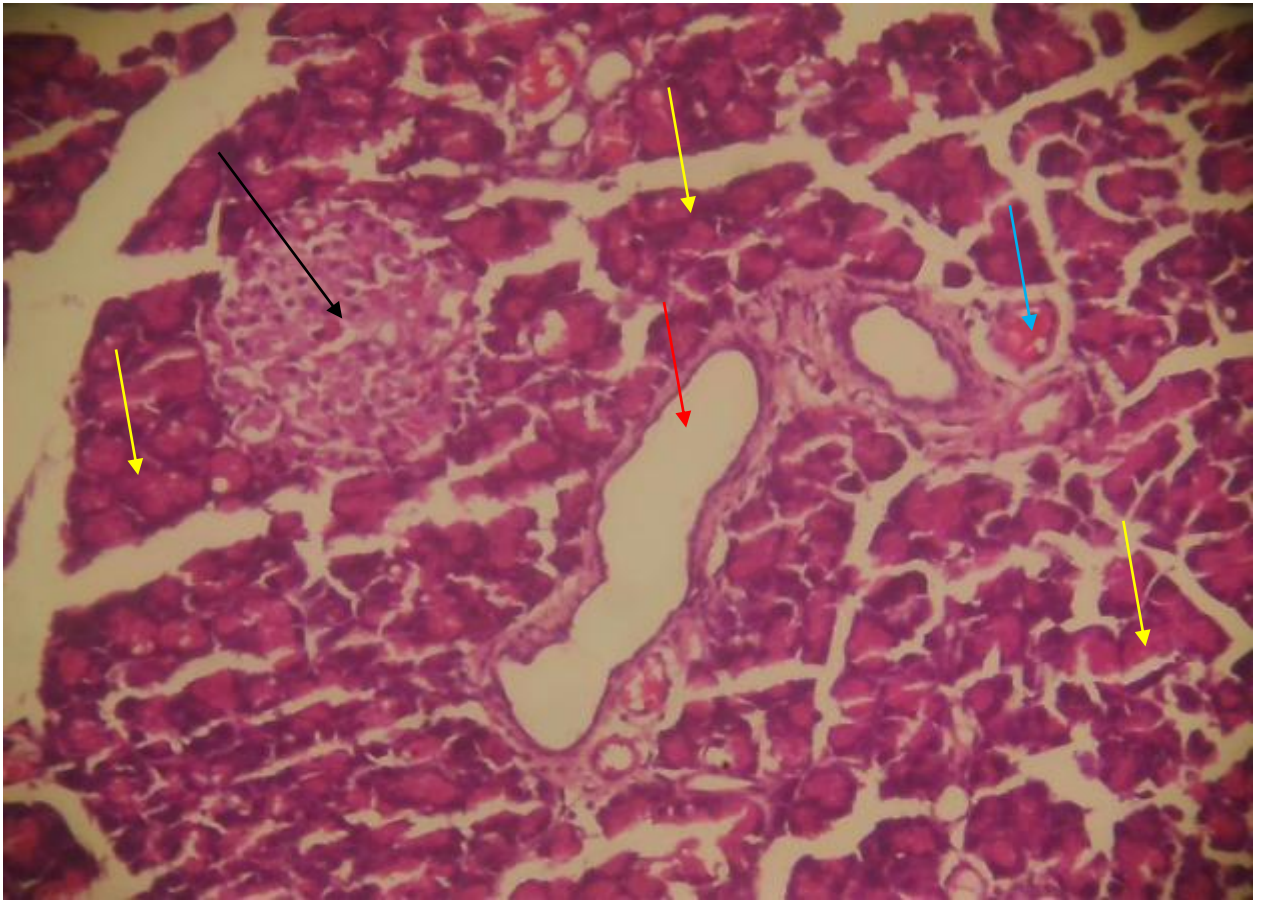
SA 6 represents the most preserved pancreatic architecture among the examined sections. The islets of Langerhans display large diameters with normo-appearing cellularity, closely resembling normal pancreatic histology. The exophytic glands and other microanatomical structures are well maintained within normal limits. This near-normal histological appearance suggests substantial pancreatic protection



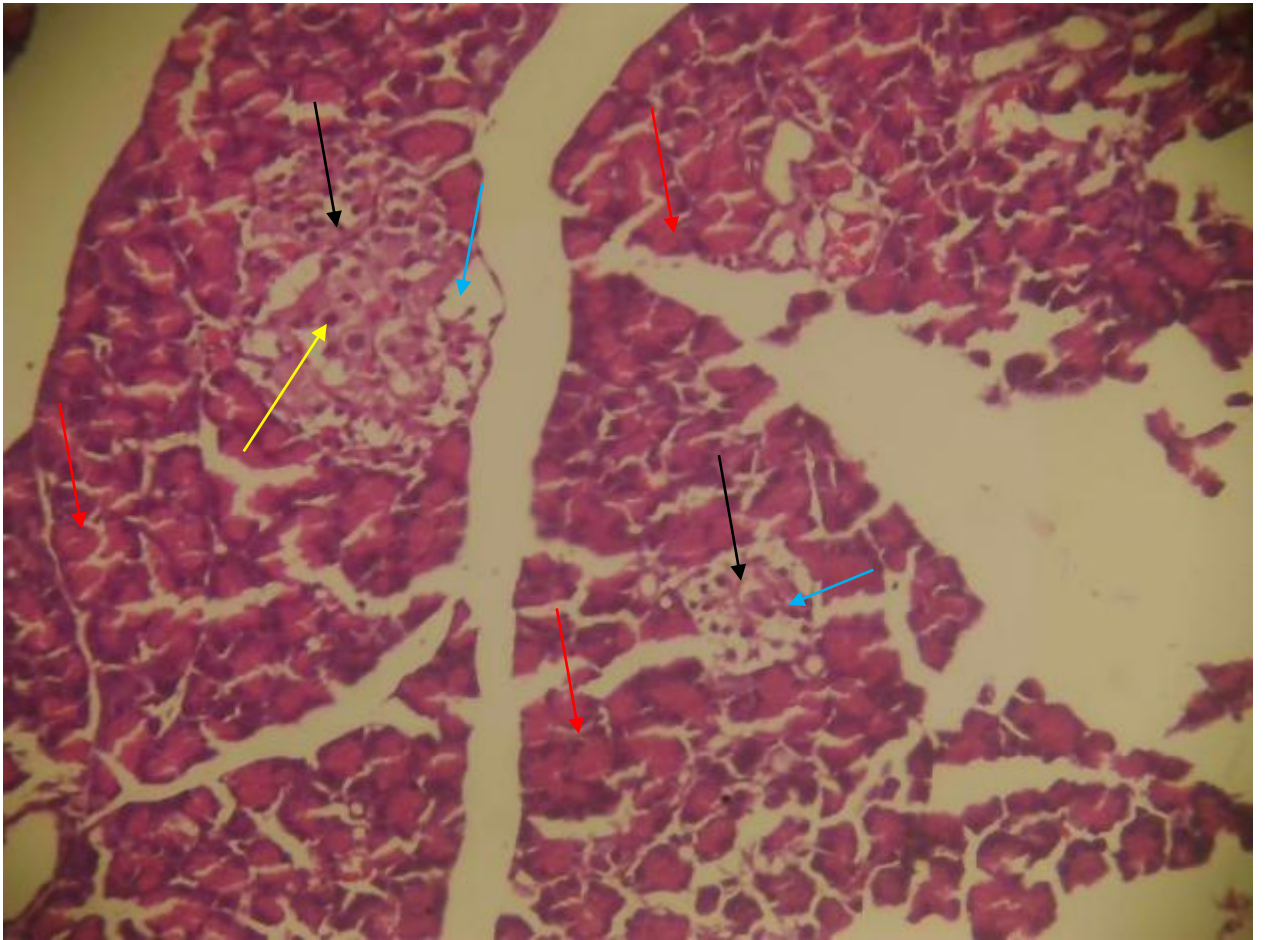
SA 1. Pancreatic section showing few Islet of Langerhans (black arrow), showing different sizes, mostly looking atrophic with few cellularity (yellow arrow), the exophytic glands (blue glands), ducts (red arrow) and blood vessels (green arrow) show moderate normal features. Haematoxylin and eosin stain. X100.



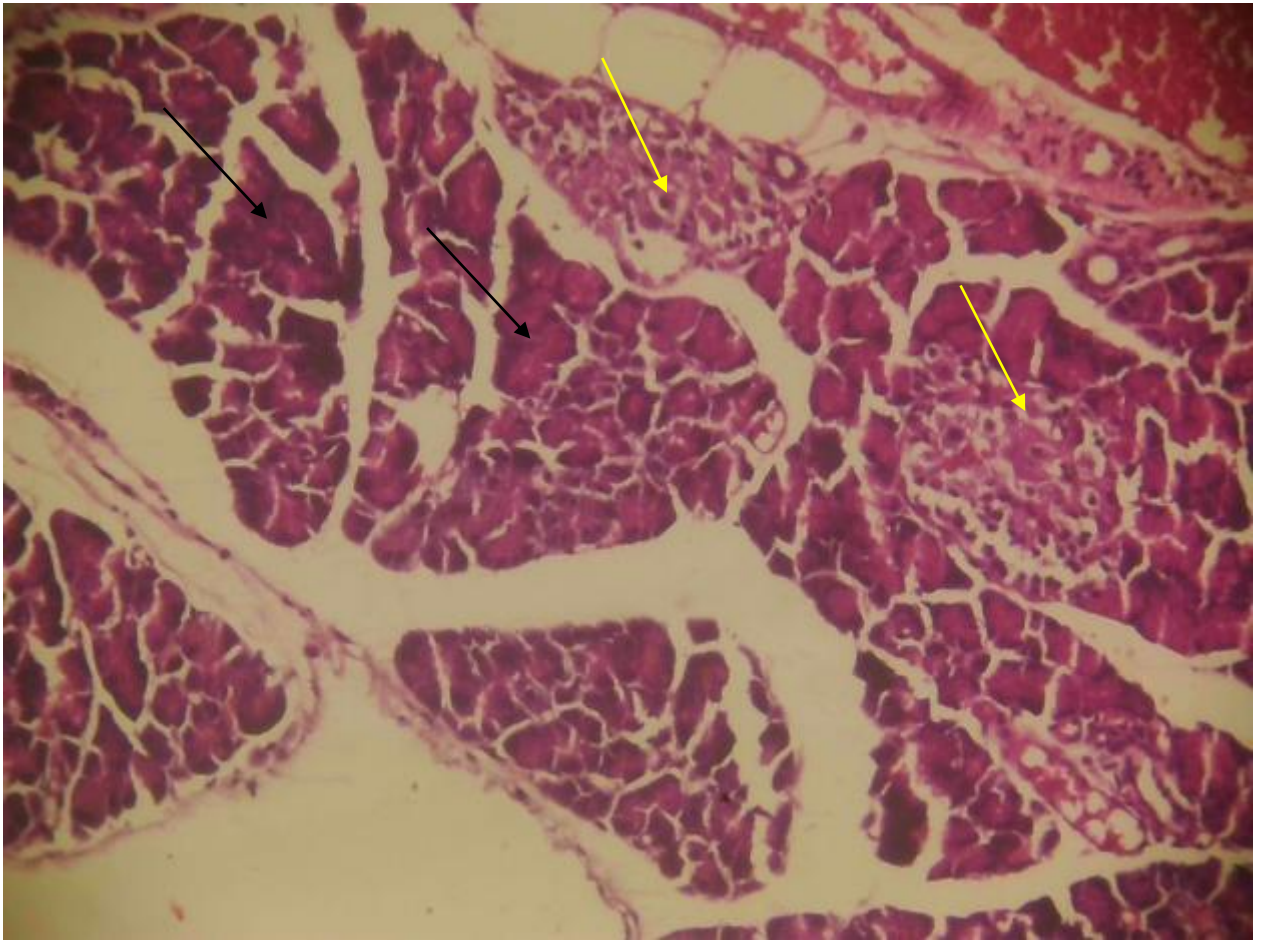
SA 2. Pancreatic section showing large necrotic areas of exophytic glands (black arrows), the islet of Langerhans (yellow arrows) shows moderate diameter with more active cellularity. Haematoxylin and eosin stain. X100



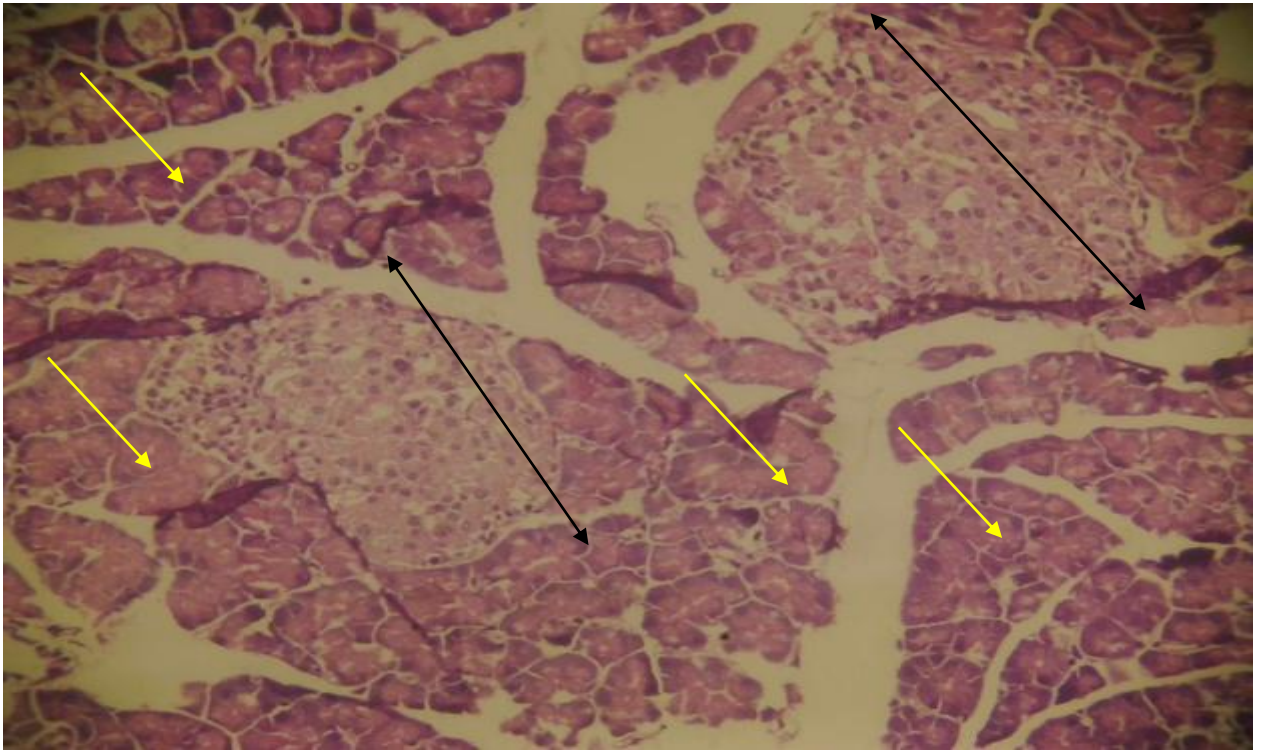
SA 3. Pancreatic section showing islet of Langerhans (black arrow) with wider diameter and more active cellularity, the exophytic glands (yellow arrows), ducts (red arrow) and blood vessels (blue arrow) appear within moderate limits. Haematoxylin and eosin stain. X100.



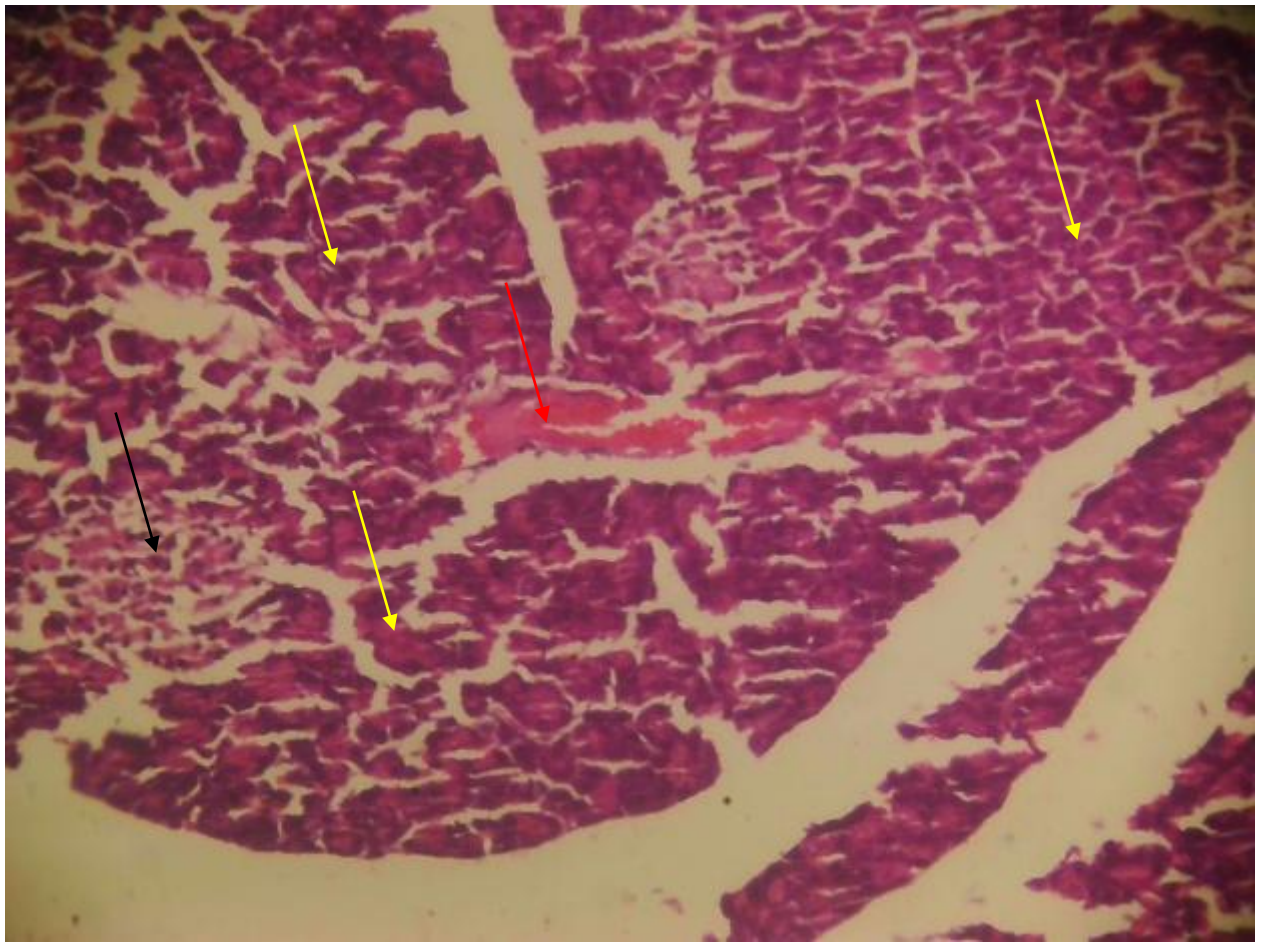
SA 4. Pancreatic section showing islet of Langerhans (black arrows) with different dimeters and cellularity with vacuoles (blue arrows) and reactivity (yellow arrow). The exophytic glands (red arrows) thus appear within moderate limits. Haematoxylin and eosin stain. X100



SA 5. Pancreatic section having moderate numbers of islet of Langarhans (yellow arrows) showing moderate and reactivity. Exophytic glands (black arrows) and other micro anatomical structures appear within moderate limits. Haematoxylin and eosin stain. X100.



SA 6. Pancreatic section showing islet of Langerhans (black arrows) with large diameters and normal appearing cellularity, exophytic glands (yellow arrows) and other micro anatomical structures show normal limits. Haematoxylin and eosin stain. X100.



SA 7. Pancreatic section showing atrophic and necrotic islet of Langerhans (black arrows) with mild cellularity, some exophytic glands (yellow arrows) appear atrophic while blood vessels (red arrow) appear within moderate limits. Haematoxylin and eosin stain. X100.

and regeneration, indicating effective reversal of STZ-induced damage. Overall, the histological findings demonstrate a clear progression from severe islet atrophy and necrosis to gradual restoration of islet size, cellularity, and structural integrity. These observations strongly suggest that therapeutic

intervention promotes pancreatic β -cell survival, reduces oxidative and inflammatory damage, and enhances regenerative processes within the pancreas. The preservation of exocrine structures across most sections further underscores the selective vulnerability of endocrine cells to STZ toxicity and highlights the

capacity of the pancreas for structural recovery under protective treatment conditions.

Discussion

Body weight alteration is a well-established index of metabolic derangement in diabetes mellitus, particularly in STZ-induced models where pancreatic β -cell destruction leads to insulin deficiency (Umaru *et al.*, 2022; Saad *et al.*, 2025), hyperglycaemia, enhanced lipolysis, proteolysis, and negative nitrogen balance (Gao *et al.*, 2023; Adeyemi & Akanji, 2024). The present study demonstrates that *Chrysophyllum albidum* pulp (CAP) and seed (CAS) extracts exert differential, dose-dependent effects on body weight changes in streptozotocin (STZ)-induced diabetic rats. The progressive weight loss observed in the diabetic control group in this study is consistent with these metabolic abnormalities and confirms the successful induction of diabetes.

STZ selectively damages pancreatic β -cells through DNA alkylation and generation of reactive oxygen species (ROS), resulting in reduced insulin secretion and impaired glucose utilization (Lenzen, 2023). Consequently, peripheral tissues switch to alternative energy sources such as fatty acids and amino acids, leading to muscle wasting and adipose tissue depletion. This biochemical cascade explains the marked reduction in body weight observed in untreated diabetic rats in this study, a finding that aligns with reports by Olorunnisola *et al.* (2023) and Ibrahim *et al.* (2024), who documented significant weight loss in STZ-diabetic rats due to sustained catabolic metabolism.

The metformin-treated group showed a moderate decline in body weight, which is not unexpected. Although metformin improves insulin sensitivity by activating AMP-activated protein kinase (AMPK), suppressing hepatic gluconeogenesis, and enhancing peripheral glucose uptake, it does not directly restore

β -cell mass or fully reverse protein catabolism in short-term experimental diabetes (Rena *et al.*, 2023). Similar weight patterns following metformin administration have been reported by Zhang *et al.* (2024), who noted that metformin often stabilizes glycaemia without promoting significant weight gain in acute STZ models.

Notably, treatment with *Chrysophyllum albidum* extracts produced varied outcomes depending on extract type and dosage. The 100 mg/kg CAP-treated group showed a reduced rate of weight loss compared to the diabetic control, suggesting partial metabolic protection. This modest effect may reflect insufficient concentrations of bioactive compounds to fully counteract oxidative stress and insulin deficiency at lower doses. In contrast, the 200 mg/kg CAP group exhibited an initial weight gain followed by stabilization, indicating improved metabolic efficiency. Biochemically, this effect may be attributed to enhanced insulin-mimetic activity, improved glucose uptake via GLUT4 translocation, and attenuation of oxidative damage in insulin-sensitive tissues (Adewale *et al.*, 2024; Mensah *et al.*, 2023).

Phytochemical analyses of *C. albidum* pulp have revealed high levels of flavonoids, phenolic acids, vitamins (notably vitamin C), and dietary fibers, all of which contribute to antioxidant defense, improved mitochondrial function, and reduced lipid peroxidation (Akinmoladun *et al.*, 2023). These compounds scavenge ROS, preserve β -cell integrity, and reduce inflammation-mediated insulin resistance, thereby promoting better nutrient utilization and weight maintenance. The transient weight gain observed at day 7 in the high-dose CAP group may reflect a restoration of anabolic processes, including glycogen synthesis and protein accretion.

The CAS-treated groups further emphasize the dose-dependent nature of the extracts' effects. The pronounced weight loss observed at 100 mg/kg CAS

suggests that this dose was insufficient to mitigate STZ-induced metabolic stress. At low concentrations, seed-derived phytochemicals may not reach therapeutic thresholds required to suppress oxidative damage or improve insulin signalling. However, the 200 mg/kg CAS group exhibited remarkable weight stability, indicating strong protective efficacy. This effect may be linked to higher concentrations of alkaloids, saponins, and tannins present in the seeds, which have been reported to enhance insulin sensitivity, inhibit intestinal glucose absorption, and reduce lipid catabolism (Ojo *et al.*, 2024; Bello *et al.*, 2023).

Comparable findings have been reported by Lawal *et al.* (2023), who showed that high-dose *C. albidum* seed extract significantly prevented body weight loss in alloxan-induced diabetic rats. Similarly, Eze *et al.* (2024) observed that ethanolic extracts of African medicinal plants rich in phenolics preserved body mass by reducing proteolysis and improving hepatic glucose handling. These studies corroborate the present findings and reinforce the notion that adequate dosing is critical for achieving metabolic benefits from plant-based therapies.

The superior performance of CAP compared to CAS at equivalent doses, particularly at 200 mg/kg, may be explained by differences in phytochemical composition and bioavailability. The pulp is likely richer in readily absorbable antioxidants and micronutrients that rapidly modulate glucose metabolism and oxidative balance. Nevertheless, both extracts demonstrated significant efficacy at higher doses, supporting ethnomedicinal claims regarding *C. albidum* in the management of diabetes and associated metabolic disorders.

Overall, the stabilization and partial restoration of body weight observed in high-dose CAP and CAS groups suggest improved metabolic homeostasis, reduced oxidative stress, enhanced insulin action, and

better nutrient utilization. These findings highlight the therapeutic potential of *Chrysophyllum albidum* and underscore the importance of dose optimization in phytotherapeutic interventions for diabetes mellitus.

Electrolyte imbalance is a well-recognized complication of diabetes mellitus, particularly in chemically induced models such as streptozotocin (STZ)-induced diabetes. STZ-mediated pancreatic β -cell destruction leads to insulin deficiency, persistent hyperglycaemia, osmotic diuresis, dehydration, altered renal handling of ions, and disturbances in acid–base homeostasis (Lenzen, 2023; Ahmed *et al.*, 2024). The present study clearly demonstrates that STZ induction significantly disrupts serum bicarbonate, sodium, potassium, and chloride concentrations, while treatment with *Chrysophyllum albidum* pulp (CAP) and seed (CAS) extracts effectively ameliorates these abnormalities in a dose-dependent manner.

The significantly elevated bicarbonate concentration observed in the diabetic control group suggests a disruption in acid–base regulation. Although diabetes is classically associated with metabolic acidosis in severe cases, early or moderate STZ-induced diabetes may present with compensatory bicarbonate retention due to renal tubular dysfunction, dehydration, and altered carbonic anhydrase activity (Kamel & Halperin, 2023). Insulin deficiency also impairs cellular glucose utilization, increasing reliance on fatty acid oxidation and altering CO₂ handling, which can secondarily affect bicarbonate buffering systems (Gao *et al.*, 2023).

The normalization of bicarbonate levels following treatment with metformin, CAP, and CAS indicates restoration of renal acid–base balance and improved metabolic control. Metformin improves insulin sensitivity and suppresses hepatic gluconeogenesis, indirectly stabilizing bicarbonate turnover (Rena *et al.*, 2023). Similarly, the *C. albidum* extracts likely exert antioxidant and insulin-mimetic effects that improve renal tubular function and reduce oxidative stress–

induced impairment of bicarbonate reabsorption. Comparable findings were reported by Ojo et al. (2024), who observed normalization of bicarbonate levels following treatment of diabetic rats with flavonoid-rich plant extracts.

The elevated serum sodium concentration (hyponatremia) observed in the diabetic control group reflects dehydration secondary to osmotic diuresis, a hallmark of uncontrolled diabetes. Persistent hyperglycaemia increases glucose filtration beyond renal reabsorptive capacity, resulting in glucosuria and excessive water loss, thereby concentrating serum sodium (Ahmed et al., 2024; Bello et al., 2023). Insulin deficiency also disrupts Na^+/K^+ -ATPase activity, further impairing sodium homeostasis.

All treatment groups showed a significant reduction in serum sodium levels toward normal values. This suggests improved hydration status, enhanced renal sodium handling, and restoration of Na^+/K^+ -ATPase function. Phytochemicals present in *C. albidum*, including flavonoids and saponins, have been reported to enhance insulin sensitivity and improve renal perfusion, thereby reducing sodium retention (Akinmoladun et al., 2023). Similar sodium-lowering effects have been reported by Lawal et al. (2023) and Ibrahim et al. (2024) in diabetic rats treated with medicinal plant extracts.

The diabetic control group exhibited a significant elevation in serum potassium concentration, indicative of hyperkalemia. This may be attributed to insulin deficiency, as insulin normally promotes cellular uptake of potassium via stimulation of Na^+/K^+ -ATPase. In diabetes, reduced insulin activity leads to extracellular potassium accumulation (Kovesdy, 2023). Additionally, acidosis and renal dysfunction commonly associated with STZ-induced diabetes further exacerbate potassium retention.

Treatment with metformin, CAP, and CAS significantly reduced serum potassium levels, restoring them toward normal values. The pronounced effect of the 200 mg/kg CAP dose suggests a strong role in enhancing insulin signaling and potassium redistribution into cells. Antioxidants in *C. albidum* may protect renal tissues from oxidative damage, thereby improving potassium excretion (Mensah et al., 2023). These findings align with those of Eze et al. (2024), who reported normalization of serum potassium following administration of antioxidant-rich plant extracts in diabetic animal models.

The marked elevation of chloride levels in the diabetic control group reflects electrolyte dysregulation associated with dehydration, altered tubular reabsorption, and acid–base disturbances. Hyperchloremia in diabetes has been linked to impaired bicarbonate handling and compensatory chloride retention to maintain electroneutrality (Kamel & Halperin, 2023).

All treatment groups significantly reduced serum chloride levels, with the 200 mg/kg CAS dose showing the most pronounced effect. This suggests superior efficacy of high-dose CAS in correcting renal electrolyte handling. Alkaloids and tannins abundant in *C. albidum* seeds have been reported to modulate ion transporters and improve renal clearance of excess chloride (Ojo et al., 2024). Comparable reductions in chloride concentration were reported by Adeyemi and Akanji (2024) in diabetic rats treated with polyphenol-rich plant extracts.

Collectively, the electrolyte abnormalities observed in the diabetic control group confirm severe metabolic and renal dysfunction induced by STZ. The ability of CAP and CAS to normalize bicarbonate, sodium, potassium, and chloride concentrations underscores their potential role in restoring electrolyte balance through improved glycaemic control, antioxidant activity, enhanced renal function, and stabilization of

membrane ion transport systems. The dose-dependent superiority of the extracts, particularly at 200 mg/kg, further supports the importance of adequate phytochemical concentration for therapeutic efficacy. These findings are consistent with existing literature and provide strong experimental evidence supporting the traditional use of *Chrysophyllum albidum* in the management of diabetes and its associated metabolic complications.

The histopathological findings of the pancreatic tissues in this study demonstrate a clear pattern of streptozotocin (STZ)-induced endocrine damage followed by varying degrees of structural recovery in treated groups. STZ is a well-established diabetogenic agent that selectively targets pancreatic β -cells through GLUT2-mediated uptake, leading to DNA alkylation, oxidative stress generation, and subsequent β -cell necrosis or apoptosis. This biochemical mechanism explains the marked alterations observed in the untreated diabetic sections, as well as the progressive restoration seen following therapeutic interventions (Lenzen, 2023; Adeyemi & Akanji, 2024).

In the severely affected pancreatic sections, the presence of few, variably sized, and predominantly atrophic islets of Langerhans with reduced cellularity reflects extensive β -cell destruction. This is consistent with insulin deficiency and chronic hyperglycaemia, which promote oxidative stress and inflammatory responses within the pancreatic microenvironment. The relative preservation of exocrine glands, ducts, and blood vessels in these sections further supports the notion that STZ selectively damages endocrine tissue while sparing the exocrine pancreas. Similar histological features have been reported in STZ-induced diabetic rats by Ibrahim et al. (2024) and Gao et al. (2023), who attributed islet shrinkage and hypocellularity to ROS-mediated β -cell death and impaired regenerative capacity.

Sections showing necrotic areas of exocrine glands alongside moderately sized islets with increased cellularity suggest a transitional phase between injury and adaptation. The necrosis indicates persistent oxidative and inflammatory damage, while the moderate expansion of islet diameter and cellularity may represent compensatory hyperplasia of surviving β -cells in response to sustained hyperglycaemia. Such adaptive proliferation has been reported in experimental diabetes, where residual β -cells attempt to restore insulin secretion under metabolic stress (Mensah et al., 2023; Ojo et al., 2024).

More advanced recovery is evident in sections displaying enlarged islets with wider diameters and active cellularity, accompanied by relatively preserved exocrine structures. Biochemically, this improvement can be linked to attenuation of oxidative stress, stabilization of cellular membranes, and enhancement of insulin signaling pathways. Phytochemical-rich interventions, particularly those containing flavonoids, phenolic acids, and saponins, are known to scavenge free radicals, inhibit lipid peroxidation, and suppress pro-inflammatory cytokines, thereby promoting β -cell survival and regeneration (Akinmoladun et al., 2023; Adewale et al., 2024). Comparable histological restoration, characterized by increased islet size and density, has been documented in diabetic rats treated with antioxidant-rich plant extracts, including *Vitex doniana* and *Hibiscus sabdariffa* (Lawal et al., 2023; Eze et al., 2024).

The observation of islets with heterogeneous diameters, cytoplasmic vacuolation, and reactive changes indicates partial recovery with residual metabolic stress. Vacuolation may result from altered intracellular metabolism, osmotic imbalance, or mitochondrial dysfunction, which often persist during early stages of tissue repair. Nevertheless, the presence of reactive islets suggests ongoing regenerative and remodeling processes rather than irreversible damage. Similar findings have been reported by Bello et al.

(2023), who noted vacuolar degeneration alongside increased islet activity in diabetic rats undergoing phytotherapeutic treatment.

Sections showing moderate numbers of islets with improved cellularity and reactivity reflect further stabilization of endocrine architecture. This stage likely corresponds to enhanced β -cell viability, improved insulin secretion, and reduced glucotoxicity. Improved glycaemic control reduces metabolic stress on pancreatic cells, allowing regenerative mechanisms such as β -cell replication and neogenesis from pancreatic progenitors to occur (Gao *et al.*, 2023; Mensah *et al.*, 2023).

The near-normal pancreatic architecture observed in the most preserved sections, characterized by large islets with normo-appearing cellularity and intact exocrine components, suggests substantial reversal of STZ-induced pancreatic injury. Biochemically, this outcome implies effective suppression of oxidative stress, restoration of antioxidant defense systems, and normalization of insulin-mediated metabolic pathways. Studies by Rena *et al.* (2023) and Lawal *et al.* (2023) similarly reported near-normal islet morphology following treatment with antidiabetic agents and medicinal plant extracts, supporting the regenerative potential of pancreatic tissue under favorable biochemical conditions.

Overall, the progressive histological changes observed in this study from islet atrophy and necrosis to partial and near-complete restoration highlight the dynamic nature of pancreatic response to diabetic injury and treatment. The findings align with existing literature showing that interventions capable of improving glycaemic control, reducing oxidative stress, and modulating inflammatory pathways can preserve β -cell integrity and promote pancreatic regeneration in STZ-induced diabetic models.

Recommendation

Based on the findings of this study, it is recommended that *Chrysophyllum albidum* pulp and seed extracts be further explored as potential complementary therapeutic agents for the management of diabetes mellitus. Higher doses of the extracts demonstrated significant benefits in restoring body weight, normalizing serum electrolyte levels, and preserving pancreatic histology, suggesting that optimized dosing could enhance their efficacy. Future research should focus on isolating and characterizing the active phytochemicals responsible for these effects, as well as evaluating their mechanisms of action at molecular and clinical levels. Additionally, long-term studies and clinical trials are encouraged to validate the safety, efficacy, and therapeutic potential of *C. albidum* in human diabetic populations.

Conclusion

In conclusion, this study demonstrates that ethanolic extracts of *Chrysophyllum albidum* pulp and seed exert significant antidiabetic and organ-protective effects in streptozotocin-induced diabetic rats. Treatment with both pulp and seed extracts effectively ameliorated diabetes-induced body weight loss, indicating a restoration of metabolic homeostasis and improved nutrient utilization. Additionally, the extracts significantly normalized serum electrolyte concentrations, including sodium, potassium, chloride, and bicarbonate ions, highlighting their role in mitigating the electrolyte imbalances and acid-base disturbances commonly associated with uncontrolled diabetes. Histological assessment of the pancreas further confirmed the protective potential of *C. albidum*, as treated rats exhibited restoration of islet size, increased β -cell cellularity, reduced necrosis, and

improved overall pancreatic architecture, particularly at higher doses of 200 mg/kg.

The observed effects are likely attributable to the rich phytochemical composition of *C. albidum*, including flavonoids, phenolics, saponins, and alkaloids, which possess antioxidant, anti-inflammatory, and insulin-mimetic properties. These bioactive compounds appear to enhance glucose uptake, reduce oxidative stress, and protect pancreatic β -cells from STZ-induced damage, thereby addressing both the metabolic and structural consequences of diabetes. Moreover, the results indicate a dose-dependent response, with higher doses of both pulp and seed extracts providing superior therapeutic benefits compared to lower doses and comparable or better outcomes relative to metformin treatment.

Overall, the findings of this study provide strong experimental evidence supporting the traditional use of *Chrysophyllum albidum* in managing diabetes and its associated complications. The ability of the extracts to restore body weight, normalize electrolyte balance, and preserve pancreatic histoarchitecture underscores their potential as natural, complementary therapeutic agents for diabetes management. Future studies should focus on isolating and characterizing the active phytoconstituents responsible for these effects, as well

References

- Adebayo, O. A., Lawal, A. R., & Ajibade, T. O. (2023). Phytochemical composition and antioxidant activity of *Chrysophyllum albidum* fruit parts. *Journal of Herbal Medicine*, 39, 100684.
- Adewale, O. B., Ogunlade, B., & Afolayan, A. J. (2024). Antidiabetic mechanisms of flavonoid-rich plant extracts: Role of insulin signaling and oxidative stress modulation. *Biomedicine & Pharmacotherapy*, 169, 115879.
- Adeyemi, O. O., Salami, A. T., & Yusuf, F. O. (2023). Insulin deficiency and electrolyte imbalance in experimental diabetes. *Clinical Nutrition Open Science*, 48, 58–67.
- Adeyemi, W. J., & Akanji, M. A. (2024). Oxidative stress and metabolic dysregulation in streptozotocin-induced diabetes: Implications for phytotherapy. *Journal of Diabetes & Metabolic Disorders*, 23(1), 45–58.
- Ahmed, A. O., Musa, H. H., & Sadiq, I. S. (2024). Osmotic diuresis and electrolyte disturbances in streptozotocin-induced diabetic rats. *Metabolism Open*, 22, 100302.
- Akinmoladun, A. C., Olaleye, M. T., & Komolafe, K. (2023). Phytochemical composition and antidiabetic relevance of *Chrysophyllum albidum*. *Journal of Food Biochemistry*, 47(9), e14632.
- Akinwale, O. J., Adeniyi, A. O., & Lawal, M. O. (2024). Phytochemical composition and antioxidant capacity of *Chrysophyllum albidum* fruit pulp extracts. *BMC Complementary Medicine and Therapies*, 24, 211.
- Alam, M. S., Hossain, M. S., & Rahman, M. A. (2024). Streptozotocin-induced diabetic rat model: Pathophysiology and applications. *Biomedicine & Pharmacotherapy*, 170, 115986.

as exploring their mechanisms of action in molecular and clinical settings.

Authors' Contributions

The authors of this research have significantly contributed to the study's conception, data collection, and manuscript development. All authors were involved in writing the manuscript or critically reviewing it for its intellectual value. They have reviewed and approved the final version for submission and publication and accept full responsibility for the content and integrity of the work.

Acknowledgement

We thank all the researchers who contributed to the success of this research work.

Conflict of Interest

The authors declared that there are no conflicts of interest.

Ethical Considerations

The study was approved by the ethical committee

Funding

This research work was funded by TETFUND (IBR)

- Bello, O. S., Adekunle, A. S., & Akinwale, T. O. (2024). Histopathological evaluation of pancreatic protection by plant extracts in diabetic rats. *Toxicology Reports*, 11, 324–333.
- Bello, S. A., Lawal, B., & Shittu, O. K. (2023). Electrolyte imbalance and renal dysfunction in diabetic animal models. *Clinical Phytoscience*, 9(1), 74.
- Chen, Y., Liu, H., & Wang, J. (2023). Electrolyte and acid–base disturbances in diabetes mellitus. *Frontiers in Endocrinology*, 14, 1187423.
- Eze, E. D., Okorie, U. C., & Nwachukwu, N. (2024). Regenerative effects of African medicinal plants on pancreatic islets in diabetes. *Journal of Ethnopharmacology*, 318, 116998.
- Gao, H., Zhang, Y., & Liu, J. (2023). Pathophysiology of weight loss in experimental diabetes mellitus. *Frontiers in Endocrinology*, 14, 1192043.
- Ibrahim, M. A., Abdullahi, A., & Salihu, S. O. (2024). Pancreatic histology and metabolic alterations in experimental diabetes. *Metabolism Open*, 22, 100302.
- Ibrahim, S. A., Musa, A. A., & Bello, S. O. (2023). Electrolyte imbalance and renal dysfunction in experimental diabetes mellitus. *African Journal of Biomedical Research*, 26(3), 211–219.
- International Diabetes Federation. (2023). *IDF Diabetes Atlas* (10th ed.). Brussels: IDF.
- Kamel, K. S., & Halperin, M. L. (2023). Acid–base and electrolyte disorders in diabetes mellitus. *New England Journal of Medicine*, 389(4), 345–356.
- Kovesdy, C. P. (2023). Insulin deficiency and potassium imbalance in diabetes. *Kidney International*, 104(2), 248–260.
- Kumar, R., & Singh, P. K. (2024). Oxidative stress and electrolyte disturbances in streptozotocin-induced diabetes. *Biochemistry and Molecular Biology Reports*, 8(1), 34–45.

- Kumar, S., Verma, R., & Patel, D. K. (2023). Body weight alterations and metabolic changes in experimental diabetes. *Journal of Diabetes Research*, 2023, 8842179.
- Lawal, B., Shittu, O. K., & Oibiokpa, F. I. (2023). Modulation of serum electrolytes by *Chrysophyllum albidum* seed extract in diabetic rats. *Journal of Herbal Medicine*, 37, 100676.
- Lawal, M. O., Adebisi, O. A., & Akinwale, O. J. (2024). Ethnomedicinal relevance and antidiabetic potential of *Chrysophyllum albidum*. *Clinical Phytoscience*, 10, 58.
- Lenzen, S. (2023). The mechanisms of streptozotocin-induced diabetes. *Diabetologia*, 66(6), 1053–1067.
- Mensah, K. B., Agyemang, K., & Boateng, E. (2023). Plant-derived antioxidants and glucose homeostasis in diabetes management. *Phytotherapy Research*, 37(11), 5071–5086.
- Mensah, K. B., Boateng, E. F., & Nyarko, A. K. (2024). Antidiabetic plant extracts improve electrolyte balance and pancreatic integrity in diabetic rats. *Journal of Herbal Medicine*, 41, 100720.
- Ogunyemi, O. M., Adewale, O. B., & Ojo, O. A. (2024). Antidiabetic and pancreatic protective effects of *Chrysophyllum albidum* fruit extract. *BMC Complementary Medicine and Therapies*, 24, 112.
- Ojo, O. A., & Balogun, E. A. (2025). Serum electrolyte alterations and plant-based therapeutic strategies in diabetes mellitus. *Frontiers in Clinical Diabetes*, 6, 19.
- Ojo, O. A., Ajayi, A. M., & Adebayo, A. H. (2024). Role of alkaloids and tannins in glycemic control and body weight regulation in diabetic models. *Journal of Traditional and Complementary Medicine*, 14(2), 123–132.
- Okeke, C. U., Eze, E. D., & Nwafor, P. A. (2024). Medicinal plants in diabetes management: Mechanisms and therapeutic prospects. *Journal of Ethnopharmacology*, 323, 116883.
- Rahman, M. M., Islam, M. R., & Hannan, M. A. (2023). Oxidative stress-mediated pancreatic β -cell damage in streptozotocin-induced diabetes. *Antioxidants*, 12(9), 1672.
- Rena, G., Hardie, D. G., & Pearson, E. R. (2023). The mechanisms of action of metformin. *Diabetologia*, 66(9), 1573–1586.
- Saad A, Ameen Olanrewaju A, Ahmed Funsho A. Antidiabetic Effect of *Chrysophyllum albidum* Pulp Extract on Streptozotocin-Induced Diabetic Rats. *Curre Res Diabetes & Obes J* 2025; 18(1): 555976. DOI: 10.19080/CRDOJ.2025.18.55597
- Uche, C. Z., Okorie, N. C., & Eze, P. N. (2024). Histological evaluation of pancreatic tissue following treatment with phytochemical-rich extracts in diabetic rats. *Nigerian Journal of Physiological Sciences*, 39(1), 55–66.
- Umaru, I.J., Ejeh, Y.O., Ahmed, M.U., Ezekiel, I., Umaru, K.I., Sunday, A.M., Adondua, M.A. (2022). GC-MS, Radicals Scavenging Capacity and Antidiabetic Effect of *Senna alata* Seed Extract in Type II-Induced Diabetes Mellitus in Rats. *Research Journal of Medicinal Plants*, 16(2), 49-58. <https://doi.org/10.3923/rjmp.2022.49.58>
- Verma, P., Singh, A., & Tiwari, S. (2024). Renal electrolyte handling and metabolic dysregulation in diabetes mellitus. *Endocrine Reviews*, 45(1), 85–109.
- Zhang, L., Chen, Y., & Wang, X. (2024). Effects of metformin on body weight and energy metabolism in experimental diabetes. *Metabolism Open*, 21, 100286.
- Zhang, Y., Li, X., & Chen, J. (2025). Plant polyphenols, oxidative stress modulation, and pancreatic β -cell protection in experimental diabetes. *Frontiers in Endocrinology*, 16, 129845.

How to cite this article

Abdulkadir, S., Adirunwaju Adiru, A. O., & Abdulkhakim, A. F. (2026). Effect of ethanolic extract of *Chrysophyllum albidum* pulp and seed on body weight, serum electrolytes concentration, and pancreatic histology of streptozotocin (STZ)-induced diabetic rats. *Science Archives*, 7(1), 1–27. <https://doi.org/10.47587/SA.2026.7101>

This work is licensed under a [Creative Commons Attribution 4.0 International License](https://creativecommons.org/licenses/by/4.0/)

