



Review Article

Alpha-Fetoprotein in Hepatocellular Carcinoma: Diagnostic Value, Prognostic Significance and Clinical Limitations

Jerry Adesola Adeyemo¹✉^{ORCID}, Micheal Abimbola Oladosu²✉^{ORCID}, Moses Adondua Abah³✉^{ORCID}

¹Department of Internal Medicine, Rems Muhr Krankenhaus, Winnenden, Germany

²Department of Chemical Sciences, Faculty of Science, Anchor University Lagos, Ayobo-Ipaja, Lagos, Nigeria

³Department of Biochemistry, Faculty of Pure and Applied Sciences, Federal University of Wukari, Wukari, Taraba State, Nigeria.

✉ Corresponding Author

Received: April 24, 2026/ Revised: May 27, 2026/Accepted: June 2, 2026

Abstract

Alpha-fetoprotein (AFP) has been extensively utilised as a serum biomarker for hepatocellular carcinoma (HCC) diagnosis and surveillance for over five decades. Despite its widespread clinical application, AFP presents significant limitations in diagnostic accuracy due to variable sensitivity and specificity across different populations and disease stages. This review comprehensively examines the biological origin of AFP, its diagnostic performance in HCC detection, the clinical interpretation of various AFP cut-off values, and the challenges posed by false-positive and false-negative results. We analyse current evidence from 2020-2025 regarding AFP's diagnostic value, prognostic significance, and clinical limitations. Understanding these aspects is crucial for optimal utilisation of AFP in clinical practice and the development of more effective diagnostic strategies for HCC. This review provides clinicians and researchers with updated insights into AFP's role in HCC management and highlights the need for complementary biomarkers and imaging modalities to enhance diagnostic accuracy.

Keywords: Alpha-fetoprotein, Hepatocellular carcinoma, Biomarker, Diagnostic accuracy, Sensitivity, Specificity, Cut-off values engineering futur

Introduction

Hepatocellular carcinoma (HCC) represents the most common primary liver malignancy and ranks as the third leading cause of cancer-related mortality globally.[1] The disease predominantly affects individuals with chronic liver disease and cirrhosis, particularly those with hepatitis B virus (HBV) and hepatitis C virus (HCV) infections, as well as non-alcoholic fatty liver disease (NAFLD).[2] Early detection of HCC significantly improves patient outcomes, with 5-year survival rates exceeding 70% for tumours detected at early stages compared to less than 20% for advanced disease.[3]

Alpha-fetoprotein (AFP), a glycoprotein first identified in the 1960s, has served as the principal serum biomarker for HCC screening and diagnosis for decades.[4] Despite its longstanding clinical utility, AFP demonstrates considerable variability in diagnostic performance, with sensitivity ranging from 40% to 65% and specificity from 76% to 94% depending on the cut-off values employed and the population studied.[5] This variability has prompted extensive research into optimising AFP utilisation and developing complementary diagnostic approaches.

The interpretation of AFP levels in clinical practice remains challenging due to several factors, including elevated AFP in

benign liver conditions, normal AFP levels in significant proportions of HCC patients, and variations in AFP production across different HCC subtypes.[6] Understanding the biological basis of AFP expression, its diagnostic limitations, and the appropriate clinical interpretation of AFP values is essential for optimal patient management. This review synthesises current evidence on AFP's diagnostic value, prognostic significance, and clinical limitations in HCC, providing a comprehensive framework for its application in contemporary clinical practice.

2. Biological Origin and Characteristics of AFP

2.1 Molecular Structure and Synthesis

AFP is a 70-kDa glycoprotein encoded by the AFP gene located on chromosome 4q25.[7] The protein comprises 591 amino acids organised into three homologous domains (I, II, and III), each containing two subdomains (A and B), structurally similar to albumin.[8] During normal foetal development, AFP is synthesized primarily by the yolk sac and foetal liver, with peak serum concentrations occurring between 12-14 weeks of gestation, reaching levels of 2-3 mg/mL.[9]

AFP expression is tightly regulated during embryonic development through complex transcriptional mechanisms involving hepatocyte nuclear factors (HNFs), CCAAT/enhancer-binding proteins (C/EBPs), and other transcription factors.[10] Following birth, AFP production decreases dramatically, with serum levels declining to less

than 10 ng/mL by 12 months of age.[11] In healthy adults, AFP concentrations typically remain below 10 ng/mL, with most individuals maintaining levels under 5 ng/mL.[12]

2.2 AFP Re-expression in Hepatocellular Carcinoma

The re-expression of AFP in HCC occurs through reactivation of the foetal hepatic gene program, a process associated with malignant transformation and dedifferentiation of hepatocytes.[13] This phenomenon results from epigenetic modifications, including DNA hypomethylation of the AFP gene promoter region and alterations in histone acetylation patterns.[14] Studies have demonstrated that AFP-producing HCC cells exhibit characteristics of hepatic progenitor cells, suggesting that AFP expression may indicate a more primitive phenotypic state.[15]

However, not all HCC tumours produce AFP, with approximately 30-40% of HCC cases presenting with normal AFP levels even in the presence of clinically significant disease. [16] This heterogeneity in AFP production correlates with tumour differentiation status, with well-differentiated HCCs generally producing less AFP compared to poorly differentiated tumours.[17] Table 1 summarises the biological characteristics and clinical ranges of AFP in various physiological and pathological conditions, while Figure 1 presents the Schematic representation of the AFP molecular structure, gene regulation, and synthesis pathways.

Table 1: Biological Characteristics and AFP Levels in Physiological and Pathological Conditions. Sources: Data from references [16,17]

Condition	AFP Levels (ng/mL)	Mechanism	Clinical Significance
Healthy adults	<10 (typically <5)	Transcriptional silencing post-natally	Normal reference range
Fetal development	2,000,000-3,000,000	Active foetal hepatic gene expression	Normal physiological
Chronic hepatitis	10-100	Hepatocyte regeneration and inflammation	False positive risk
Liver cirrhosis	10-200	Chronic regeneration, dysplasia	Intermediate elevation
Early-stage HCC	Often <20 (20-30% of cases)	Variable AFP gene reactivation	False negative risk
Advanced HCC	>400 (60-80% of cases)	Complete foetal gene program reactivation	High diagnostic specificity
Pregnancy (3rd trimester)	100-500	Foetal production	Normal physiological
Germ cell tumours	>1000 (variable)	Tumour production (yolk sac elements)	Extra-hepatic source

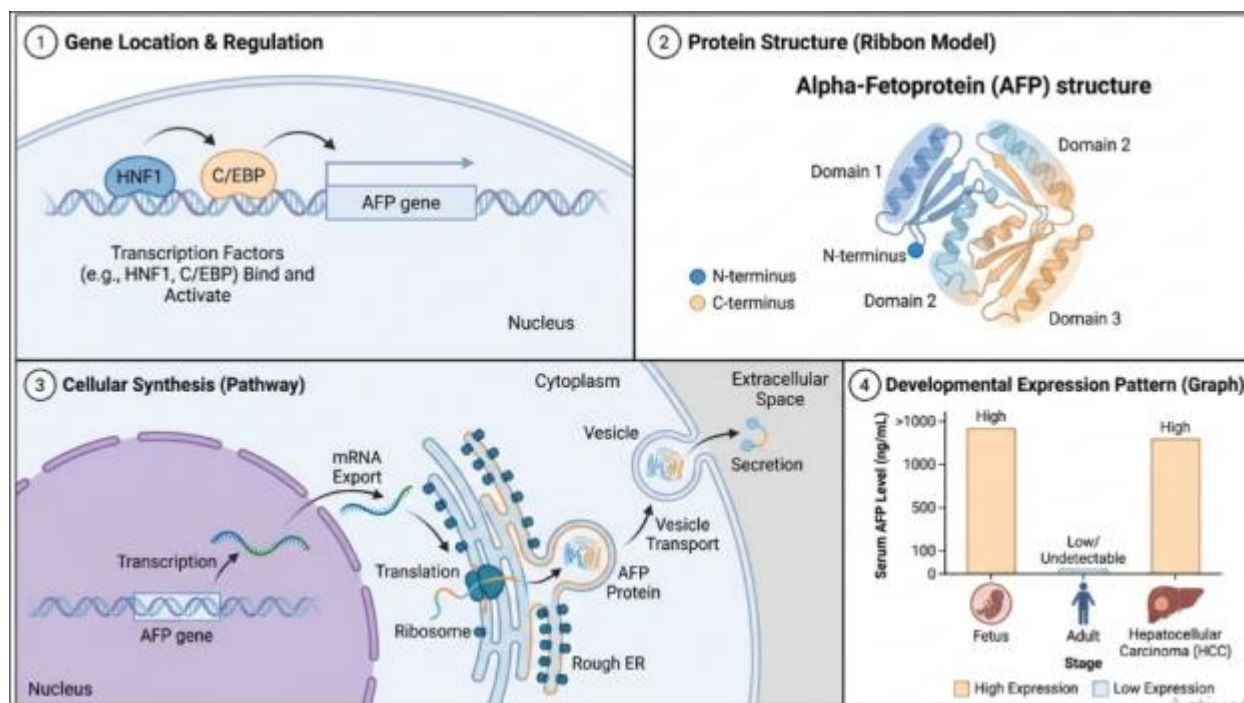


Figure 1: Schematic representation of AFP molecular structure, gene regulation, and synthesis pathways. [18].

3. Diagnostic Value: Sensitivity and Specificity

3.1 Diagnostic Performance Characteristics

The diagnostic performance of AFP for HCC detection exhibits substantial variation depending on the cut-off value selected, the prevalence of cirrhosis in the study population, and the stage of HCC at detection.[19] Meta-analyses conducted between 2020-2025 have reported pooled sensitivity values ranging from 41% to 65% and specificity from 80% to 94% for AFP cut-off values between 10-400 ng/mL.[20] This wide performance range underscores the challenge of establishing universal AFP thresholds for HCC diagnosis.

At the traditionally employed cut-off of 20 ng/mL, AFP demonstrates sensitivity of approximately 60% and specificity of 85% for HCC detection in cirrhotic patients.[21] However, this threshold fails to detect up to 40% of HCC cases, particularly early-stage tumours, which frequently present with normal or minimally elevated AFP

levels.[22] Conversely, lowering the cut-off to 10 ng/mL improves sensitivity to approximately 70% but reduces specificity to 76%, resulting in increased false-positive results, particularly in patients with active liver inflammation.[23]

Higher AFP cut-off values, such as 200 ng/mL or 400 ng/mL, provide greater specificity (>95%) but significantly reduce sensitivity (<40%), limiting their utility for screening purposes while potentially serving as diagnostic thresholds in

specific clinical contexts.[24] Recent studies have explored dynamic AFP changes over time, demonstrating that AFP velocity and doubling time may enhance diagnostic accuracy beyond single-point measurements.[25] Table 2 presents comprehensive sensitivity and specificity data for various AFP cut-off values based on recent literature, while Figure 2 illustrates the Receiver operating characteristic (ROC) curves comparing the diagnostic performance of different AFP cut-off values for HCC detection.

Table 2: Sensitivity and Specificity of AFP at Different Cut-off Values for HCC Diagnosis [19-25]

AFP Cut-off (ng/mL)	Sensitivity (%)	Specificity (%)	PPV (%)	NPV (%)
10	65-70	76-82	25-35	92-95
20	55-65	85-90	40-50	91-94
100	48-55	92-95	55-65	89-92
200	32-40	95-98	70-80	86-89
400	25-35	97-99	80-90	84-87

PPV = Positive Predictive Value; NPV = Negative Predictive Value. Values represent ranges from recent meta-analyses

(2020-2025) in cirrhotic populations. Actual values vary based on HCC prevalence and population characteristics.

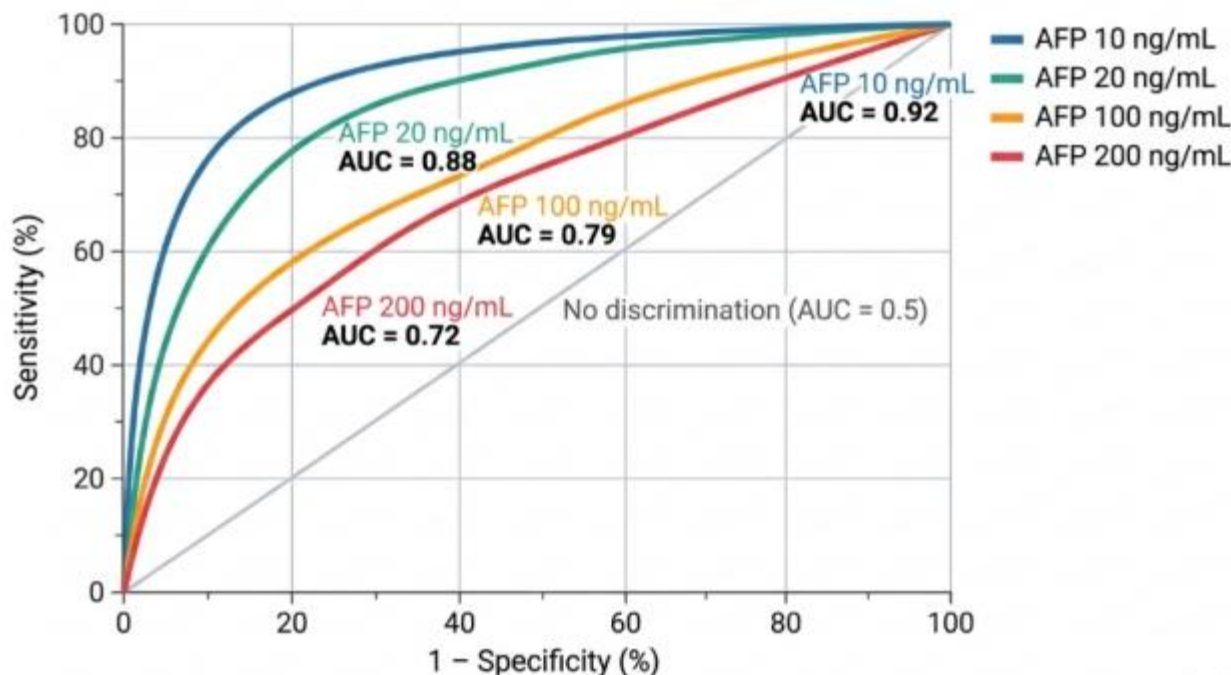


Figure 2: Receiver operating characteristic (ROC) curves comparing diagnostic performance of different AFP cut-off values for HCC detection.[26]

3.2 Factors Affecting Diagnostic Accuracy

Multiple factors influence AFP diagnostic performance in HCC detection. Tumour size significantly impacts AFP elevation, with tumours smaller than 2 cm demonstrating AFP elevation in only 20-30% of cases, compared to 60-80% in tumours larger than 5 cm.²⁷ Tumour differentiation also correlates with AFP production, as poorly differentiated HCCs exhibit higher AFP expression compared to well-differentiated variants.^[28]

The underlying aetiology of liver disease affects AFP baseline levels and test performance. Patients with HBV-related cirrhosis demonstrate higher baseline AFP levels compared to HCV or alcohol-related cirrhosis, potentially reducing specificity in HBV populations.^[29] Additionally,

the presence of active hepatic inflammation, as indicated by elevated transaminases, frequently causes transient AFP

elevation independent of HCC, complicating interpretation.^[30]

Geographic and ethnic variations in HCC characteristics also influence AFP performance. Asian populations with predominantly HBV-related HCC show different AFP patterns compared to Western populations with more diverse etiologies.^[31] These population-specific differences necessitate consideration of local epidemiology when interpreting AFP results and establishing screening protocols.

4. AFP Cut-Off Values and Clinical Interpretation

4.1 Standard Cut-off Values and Guidelines

Clinical guidelines from major hepatology societies provide varying recommendations for AFP cut-off values in HCC diagnosis and surveillance. The American Association for the Study of Liver Diseases (AASLD) no longer recommends

AFP alone for HCC screening but acknowledges its value when combined with imaging.[32] The European Association for the Study of the Liver (EASL) suggests that AFP levels above 200 ng/mL in high-risk patients with cirrhosis warrant investigation for HCC even without definitive imaging findings.[33]

The Asian Pacific Association for the Study of the Liver (APASL) recommends using AFP at a cut-off of 20 ng/mL in combination with ultrasound for HCC surveillance in high-risk populations.[34] In clinical practice, AFP values are typically interpreted within a clinical context: levels below 20 ng/mL are generally considered normal, 20-200 ng/mL

warrant further investigation, and levels above 200 ng/mL in cirrhotic patients are highly suggestive of HCC.[35] Recent evidence supports the utility of AFP-L3 (Lens culinaris agglutinin-reactive AFP) percentage and des-gamma-carboxy prothrombin (DCP) as complementary biomarkers to improve diagnostic accuracy. The combination of AFP, AFP-L3, and DCP (GALAD score) demonstrates superior performance compared to AFP alone, with area under the curve (AUC) values exceeding 0.90 in several studies.[36] Table 3 provides a comprehensive framework for clinical interpretation of AFP values across different scenarios, while Figure 3 shows the Box-and-whisker plots comparing AFP levels across different clinical scenarios.

Table 3: Clinical Interpretation of AFP Levels in Different Clinical Scenarios

AFP Level (ng/mL)	Clinical Scenario	Probability of HCC	Recommended Clinical Action	Key Considerations
<10	Healthy adult, no liver disease	Very low (<1%)	Routine surveillance per risk status; no immediate workup required	Reassuring if no risk factors; continue standard monitoring
10-20	Chronic hepatitis or cirrhosis without active inflammation	Low (1-5%)	Repeat AFP in 3 months; ultrasound surveillance every 6 months	May reflect hepatocyte regeneration; correlation with liver function tests recommended
20-100	Cirrhotic patient with or without active hepatitis	Moderate (10-25%)	Urgent ultrasound; if negative, consider CT/MRI; hepatology referral	Overlap with benign inflammation; active HBV/HCV flare should be excluded
100-200	High-risk cirrhotic patient (HBV/HCV-related)	High (30-50%)	Triphasic CT or dynamic MRI within 4 weeks; multidisciplinary team review	Consider AFP-L3% and DCP testing; biopsy if imaging inconclusive
>200	Cirrhotic patient with or without liver mass on imaging	Very high (>80%)	Immediate advanced imaging (CT/MRI); initiate HCC diagnostic workup	Level >200 ng/mL in cirrhosis is near-diagnostic per EASL guidelines; staging required
>400	Any patient with chronic liver disease or suspected mass	Highly suggestive (>90%)	Urgent HCC staging workup; refer to HCC specialist	Exclude extrahepatic sources (germ cell tumours); consider portal vein thrombosis assessment
Rising trend (any level)	Post-treatment surveillance or active monitoring	Variable; elevated recurrence risk	Serial imaging; reassess treatment response; consider re-treatment or palliative options	AFP velocity >10 ng/mL/year or doubling time <60 days indicates high recurrence risk
Declining after treatment	Post-resection, ablation, or systemic therapy	Favourable prognostic indicator	Continue surveillance imaging every 3 months; assess complete response	AFP normalisation correlates with improved outcomes; persistent elevation suggests residual disease

AFP = alpha-fetoprotein; HCC = hepatocellular carcinoma; HBV = hepatitis B virus; HCV = hepatitis C virus; CT = computed tomography; MRI = magnetic resonance imaging; DCP = des-gamma-carboxy prothrombin; AFP-L3 = Lens

culinaris agglutinin-reactive AFP fraction. AFP thresholds interpreted within clinical context; absolute values may vary by assay platform and laboratory reference range.

Sources: Compiled from references [32-36,38,39]

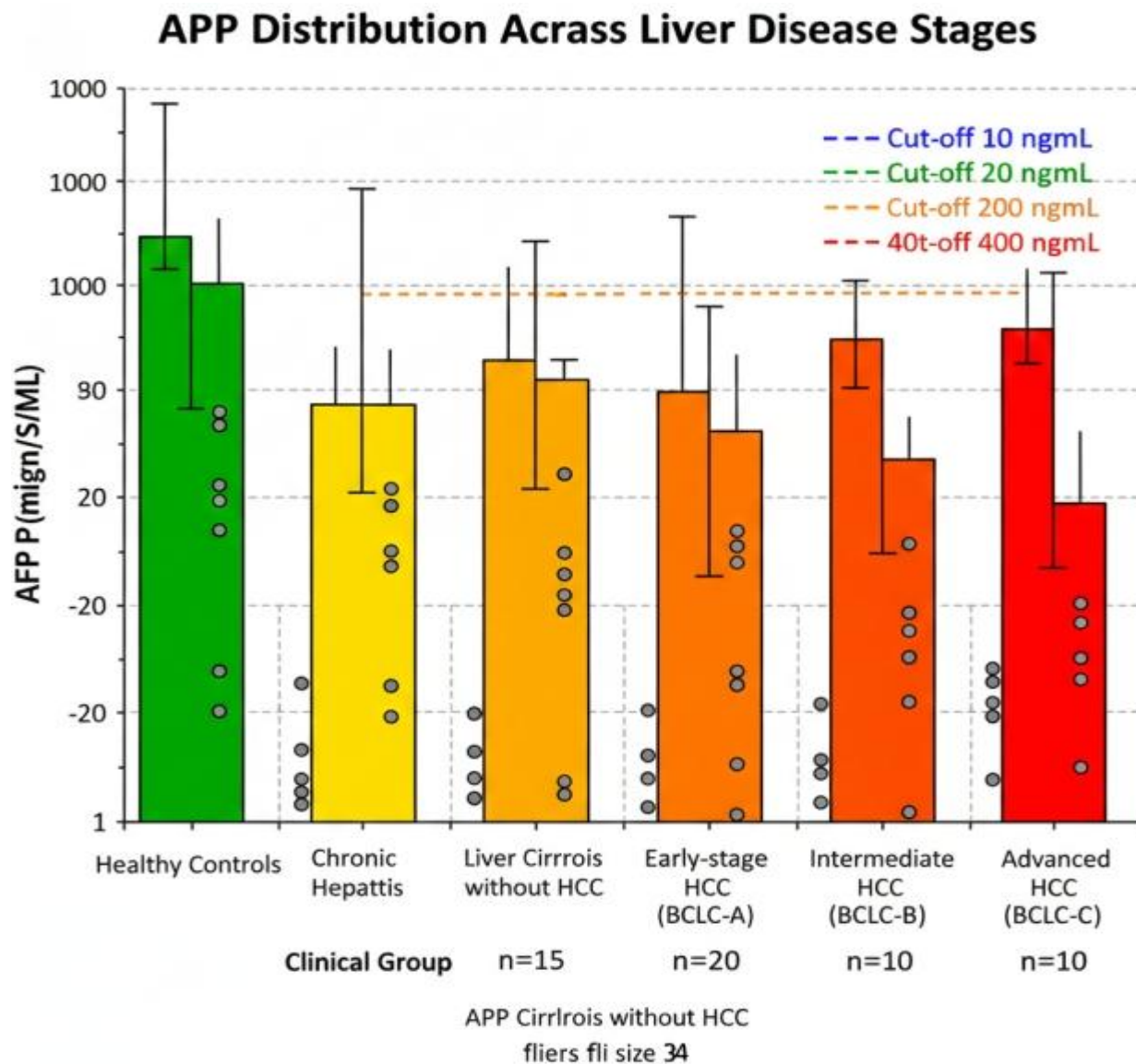


Figure 3: Box-and-whisker plots comparing AFP levels across different clinical scenarios.[37]

4.2 Dynamic AFP Monitoring

Serial AFP measurements and calculation of AFP kinetics provide additional diagnostic and prognostic information beyond single-point values. AFP doubling time less than 60 days strongly suggests HCC development in cirrhotic patients, even when absolute AFP levels remain below conventional diagnostic thresholds.[38] Studies have demonstrated that AFP velocity (the rate of change over time) improves early HCC detection, with values exceeding 10 ng/mL per year indicating an increased risk of HCC.[39] The clinical utility of AFP monitoring extends to treatment response assessment and recurrence detection following HCC therapy. Post-treatment AFP normalisation correlates with favourable outcomes, while persistent elevation or secondary rise indicates incomplete treatment response or disease

recurrence.[40] Integration of AFP kinetics into surveillance protocols may enhance early detection rates, particularly in patients with persistently normal or minimally elevated AFP levels.

5. False Positives and False Negatives

5.1 False-Positive AFP Elevation

False-positive AFP elevation represents a significant challenge in HCC diagnosis, occurring in various benign hepatic and non-hepatic conditions. Chronic viral hepatitis, particularly during active inflammation or treatment, commonly causes AFP elevation without HCC presence.[41] Hepatic flares in HBV-infected patients can produce AFP

levels exceeding 100 ng/mL, creating diagnostic uncertainty and necessitating careful clinical correlation. [42]

Other benign conditions associated with false-positive AFP include acute liver injury from various causes, hepatic regeneration following partial hepatectomy, and certain benign liver tumours such as hepatic adenomas.[43] Pregnancy represents a physiological cause of AFP elevation, with levels typically remaining below 500 ng/mL but occasionally reaching higher values.[44] Germ cell tumours, particularly testicular and ovarian neoplasms, can produce significant AFP elevation, highlighting the importance of considering extra-hepatic sources in appropriate clinical contexts.[45]

The specificity of AFP testing improves considerably at higher cut-off values, with levels exceeding 400 ng/mL demonstrating specificity greater than 95% for HCC in cirrhotic patients.[46] However, this approach sacrifices sensitivity, missing a substantial proportion of early-stage HCCs. Complementary testing with AFP-L3 percentage and DCP can help differentiate true HCC-related AFP elevation from benign causes, as these markers show greater specificity for malignant disease.[47]

5.2 False-Negative Results

False-negative AFP results occur in approximately 30-40% of HCC cases, representing a critical limitation of AFP-based screening.[48] Several HCC subtypes demonstrate characteristically low or absent AFP production. Well-

differentiated HCCs, comprising 20-30% of tumours, frequently present with normal AFP levels despite clinically significant disease.[49] Similarly, fibrolamellar HCC, a rare variant affecting younger patients without underlying cirrhosis, typically produces minimal AFP. [50]

Small, early-stage HCCs (≤ 2 cm) demonstrate AFP elevation in only 20-30% of cases, severely limiting AFP's utility for early detection in surveillance programs.[51] This size-dependent AFP expression pattern contributes to delayed diagnosis in patients screened with AFP alone, potentially missing the optimal therapeutic window for curative interventions. Molecular subtyping studies have identified specific HCC classes with consistently low AFP expression, associated with distinct genetic profiles and clinical behaviours. [52]

The substantial false-negative rate of AFP underscores the necessity of combining biomarker testing with imaging surveillance. Current guidelines recommend ultrasound-based surveillance every 6 months for at-risk populations, with or without AFP measurement.[53] However, ultrasound alone demonstrates suboptimal sensitivity (45-84%), particularly in patients with obesity, advanced cirrhosis, or nodular liver surface, suggesting that optimal screening requires multimodal approaches incorporating biomarkers and imaging.[54] Table 4 summarises common causes of false-positive and false-negative AFP results with their clinical significance, and Figure 4 presents the Clinical diagnostic algorithm integrating AFP with imaging modalities for HCC diagnosis.

Table 4: Common Causes of False-Positive and False-Negative AFP Results in HCC Diagnosis [41-54]

Category	Condition / Cause	Typical AFP Range (ng/mL)	Clinical Significance and Management
FALSE POSITIVE	Chronic viral hepatitis (HBV/HCV) with active inflammation	20-200 (occasionally >500 during flares)	AFP elevation reflects hepatocyte damage and regeneration, not malignancy; it correlates with transaminases and viral load; repeat after inflammation resolves
FALSE POSITIVE	Hepatitis B virus reactivation / acute flare	50-500 (may transiently exceed 1000)	Acute HBV flares can produce dramatic AFP rise; clinical context and HBV DNA levels are essential; AFP typically normalises with flare resolution
FALSE POSITIVE	Liver cirrhosis (any aetiology)	10-200	Chronic regenerative activity elevates AFP in the absence of HCC; baseline AFP should be established in all cirrhotic patients for trend monitoring
FALSE POSITIVE	Non-alcoholic steatohepatitis (NASH) / NAFLD	10-100	Hepatic inflammation and metabolic dysregulation can mildly elevate AFP; consider complementary biomarkers (AFP-L3, DCP) for disambiguation
FALSE POSITIVE	Acute liver injury (drug-induced, ischaemic, autoimmune)	20-500 (variable)	Massive hepatocyte injury and regeneration transiently raise AFP; clinical history and liver biopsy may be required to exclude malignancy
FALSE	Post-hepatectomy	20-300 (peaks 1-2)	Expected physiological elevation following

POSITIVE	hepatic regeneration	weeks post-op)	partial liver resection; interpret cautiously in post-resection HCC surveillance
FALSE POSITIVE	Pregnancy (second and third trimester)	100-500 (foetal production)	Physiological AFP rise from the foetus-placental unit; should not be used for HCC surveillance during pregnancy without clinical caution
FALSE POSITIVE	Germ cell tumours (testicular, ovarian yolk sac elements)	100 to >10,000 (highly variable)	Extra-hepatic AFP production; scrotal/pelvic imaging and beta-hCG measurement required to exclude germinal malignancy
FALSE POSITIVE	AFP-producing gastric or colorectal carcinoma (rare)	50-1000 (rare)	Rare AFP-secreting gastrointestinal cancers; cross-sectional imaging and endoscopy are essential in non-cirrhotic patients
FALSE NEGATIVE	Early-stage HCC (tumour 2 cm or less)	Normal (below 20) in 70-80% of cases	Small HCCs frequently lack sufficient AFP-secreting tumour mass; ultrasound or MRI is essential; do not rely on AFP alone for early detection
FALSE NEGATIVE	Well-differentiated HCC	Normal or minimally elevated (typically below 20)	Differentiated tumour cells retain regulatory suppression of AFP gene; these tumours may be missed on AFP-based screening
FALSE NEGATIVE	Fibrolamellar HCC	Normal (below 10) in over 95% of cases	Distinct variant lacking foetal gene program reactivation; CT/MRI and biopsy required; predominantly affects young non-cirrhotic patients
FALSE NEGATIVE	AFP-negative HCC molecular subtype	Normal (below 20) in 30-40% of all HCC	Specific transcriptomic HCC subclasses constitutively suppress AFP; imaging surveillance and novel biomarkers (DCP, AFP-L3) are critical
FALSE NEGATIVE	HCC in advanced cirrhosis with low tumour burden	Below threshold despite tumour presence	Competing regenerative liver disease may mask HCC-specific AFP signal; AFP-L3 fraction may be more informative
FALSE NEGATIVE	HCC in non-cirrhotic liver	Normal in 40-50% of cases	HCC arising in non-fibrotic liver (e.g., HBV-related in Asia) may not trigger AFP elevation; imaging and biopsy are the cornerstones of diagnosis

AFP = alpha-fetoprotein; HCC = hepatocellular carcinoma; HBV = hepatitis B virus; HCV = hepatitis C virus; NASH = non-alcoholic steatohepatitis; NAFLD = non-alcoholic fatty liver disease; DCP = des-gamma-carboxy prothrombin;

AFP-L3 = *Lens culinaris* agglutinin-reactive AFP fraction. Orange shading = false-positive causes; blue shading = false-negative causes. [41-54]

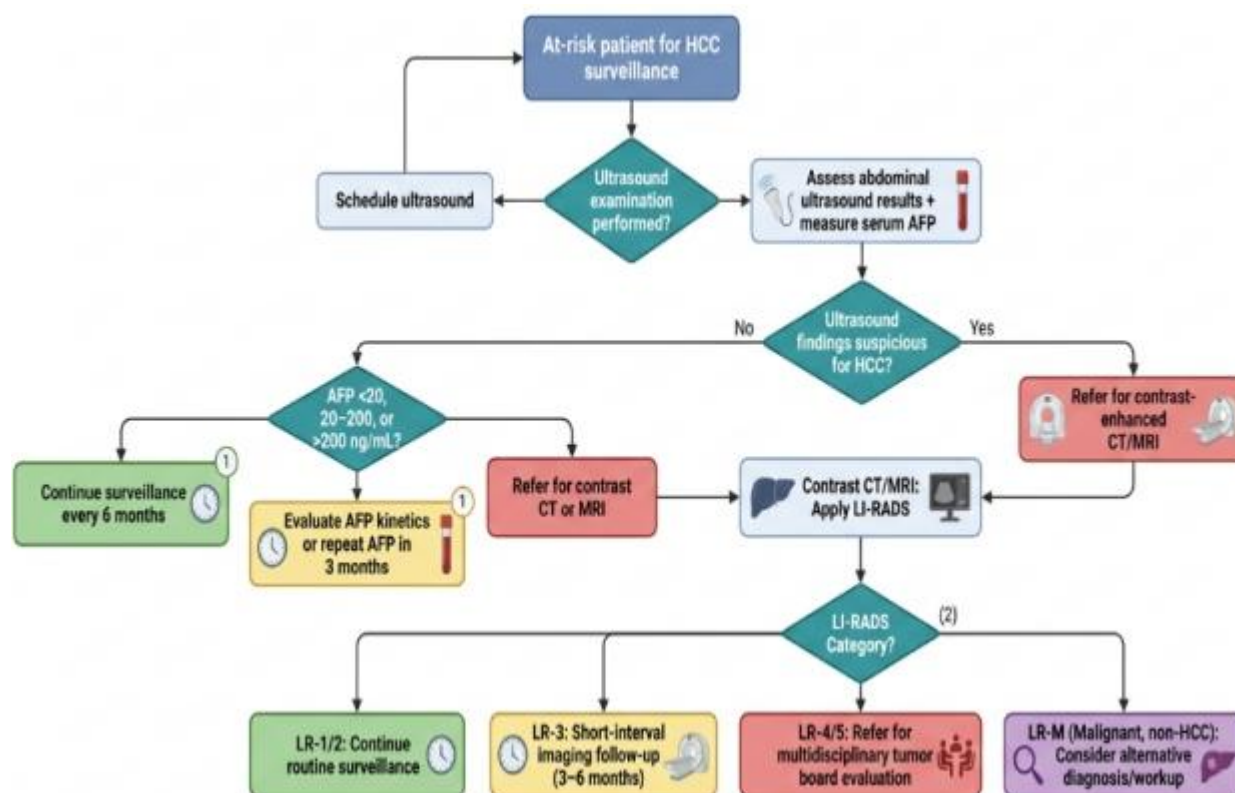


Figure 4: Clinical diagnostic algorithm integrating AFP with imaging modalities for HCC diagnosis. [55].

6. Prognostic Significance of AFP in HCC

Beyond its diagnostic role, AFP demonstrates significant prognostic value in HCC management. Elevated pre-treatment AFP levels correlate independently with tumor aggressiveness, vascular invasion, and reduced overall survival across various treatment modalities.⁵⁶ Patients with AFP levels exceeding 400 ng/mL at diagnosis show significantly worse outcomes compared to those with lower values, independent of tumor stage and treatment received.⁵⁷ AFP serves as a valuable biomarker for predicting treatment response and post-treatment recurrence. Following surgical resection or liver transplantation, persistent AFP elevation indicates residual disease or increased recurrence risk.⁵⁸

AFP response to systemic therapy, particularly with tyrosine kinase inhibitors and immunotherapy, correlates with radiological response and survival outcomes, providing early indication of treatment efficacy.⁵⁹

Several prognostic models incorporate AFP as a key variable, including the CLIP score, GALAD score, and various recurrence prediction algorithms.⁶⁰ Post-treatment AFP normalization represents a favorable prognostic indicator, while rapid AFP rise following treatment suggests early recurrence or progression. Integration of AFP kinetics into prognostic assessments enhances their predictive accuracy, particularly when combined with imaging and clinical parameters.⁶¹

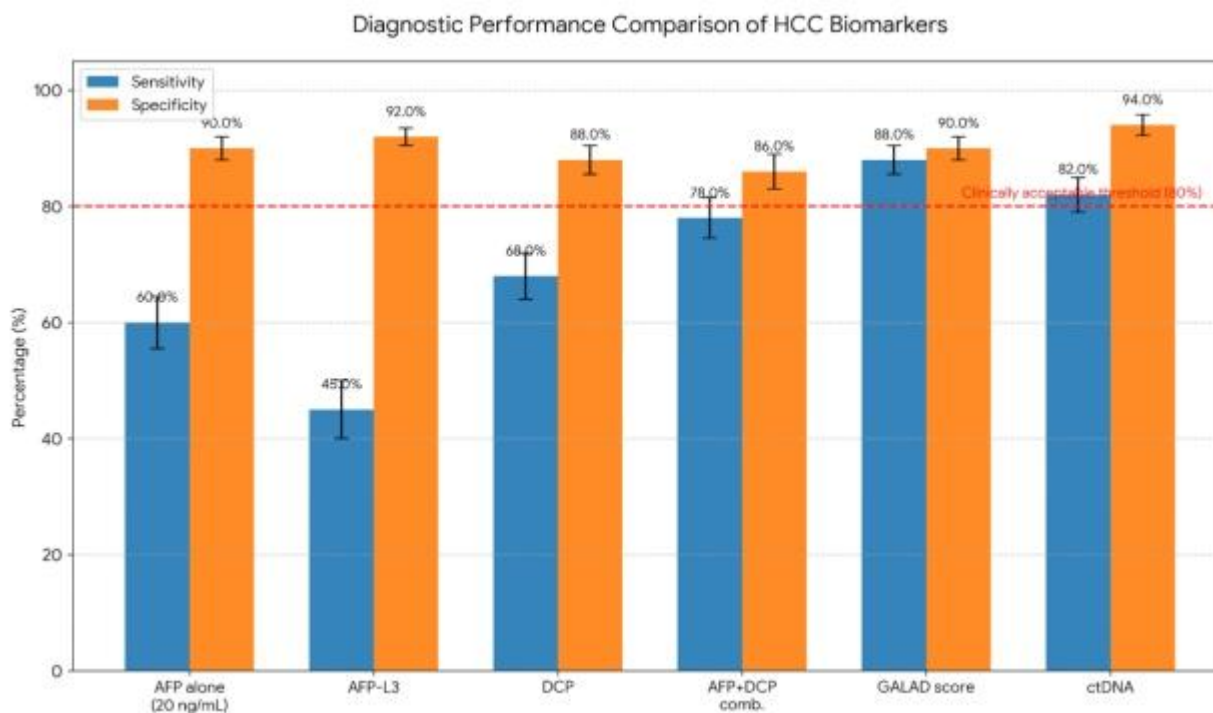


Figure 5: Comparative diagnostic performance of AFP versus novel biomarkers and combinations. [62]

7. Clinical Limitations and Future Directions

Despite decades of clinical use, AFP presents several inherent limitations that restrict its utility as a standalone HCC biomarker. The substantial overlap in AFP levels between HCC and benign liver conditions compromises specificity, while the high frequency of AFP-negative HCC reduces sensitivity.[63] These limitations become particularly problematic in surveillance settings where early detection is crucial, but AFP performance is suboptimal.

The lack of standardisation in AFP assays across laboratories contributes to result variability and interpretation challenges. Different immunoassay platforms may produce discordant results for the same sample, potentially affecting clinical decision-making.[64] Additionally, AFP does not effectively discriminate between intrahepatic cholangiocarcinoma and HCC, both of which may present as liver masses in cirrhotic patients. [65]

Future directions in HCC biomarker research focus on developing more sensitive and specific alternatives or complements to AFP. Emerging biomarkers, including circulating tumour DNA, exosomal microRNAs, and proteomics panels, show promise in early studies but require validation in large prospective cohorts.[66] Machine learning approaches integrating multiple biomarkers with clinical and imaging data may enhance diagnostic accuracy beyond current standards.[67]

The optimal approach to HCC surveillance likely involves multimodal strategies combining biomarkers, imaging, and risk stratification tools. Development of population-specific surveillance protocols accounting for regional differences in HCC epidemiology, aetiology, and healthcare infrastructure represents an important goal for improving early detection rates globally.[68] Continued research into AFP biology and its relationship with HCC pathogenesis may identify novel therapeutic targets and refine its clinical application.

8. Conclusion

Alpha-fetoprotein remains a valuable but imperfect biomarker in HCC management, with clear diagnostic and prognostic utility tempered by significant limitations. Understanding the biological basis of AFP expression, appropriate interpretation of AFP values, and recognition of false-positive and false-negative scenarios are essential for optimal clinical application. The variable sensitivity and specificity of AFP across different cut-off values necessitates individualized interpretation based on clinical context, underlying liver disease etiology, and tumor characteristics. Current evidence supports using AFP as a complementary tool alongside imaging surveillance rather than as a standalone screening test. Integration of AFP with novel biomarkers and advanced imaging modalities offers promise for improving HCC detection rates and patient outcomes. Continued research into AFP biology, assay standardisation, and development of superior biomarkers will further refine HCC diagnostic approaches. Clinicians should recognise both

the value and limitations of AFP, applying this knowledge to provide optimal care for patients at risk for HCC.

Acknowledgments

The authors acknowledge the contribution of prior empirical studies synthesised in this systematic review.

Author Contributions

The author has significantly contributed to the study's conception, design, data collection, analysis, and interpretation. All authors were involved in writing the manuscript or critically reviewing it for its intellectual value. They have reviewed and approved the final version for submission and publication and accept full responsibility for the content and integrity of the work.

Financial Support

The authors declare that no external funding was received for this study.

Conflicts of Interest

The authors state that there are no financial, personal, or professional conflicts of interest associated with this research.

Ethical Approvals

This research did not involve the use of human participants or animal subjects and therefore did not require ethical clearance

Publisher's Note

The Journal stays neutral about jurisdictional claims in published maps and institutional affiliations

References

- Sung H, Ferlay J, Siegel RL, Laversanne M, Soerjomataram I, Jemal A, et al. Global cancer statistics 2020: GLOBOCAN estimates of incidence and mortality worldwide for 36 cancers in 185 countries. *CA Cancer J Clin.* 2021;71(3):209-49. DOI: 10.3322/caac.21660
- Anstee QM, Reeves HL, Kotsiliti E, Govaere O, Heikenwalder M. From NASH to HCC: current concepts and future challenges. *Nat Rev Gastroenterol Hepatol.* 2019;16(7):411-28. DOI: 10.1038/s41575-019-0145-7
- Llovet JM, Kelley RK, Villanueva A, Singal AG, Pikarsky E, Roayaie S, et al. Hepatocellular carcinoma. *Nat Rev Dis Primers.* 2021;7(1):6. DOI: 10.1038/s41572-020-00240-3
- Mizejewski GJ. Biological role of alpha-fetoprotein in cancer: prospects for anticancer therapy. *Expert Rev Anticancer Ther.* 2002;2(6):709-35. DOI: 10.1586/14737140.2.6.709
- Yang JD, Heimbach JK. New advances in the diagnosis and management of hepatocellular carcinoma. *BMJ.* 2020;371:m3544. DOI: 10.1136/bmj.m3544
- Tzartzeva K, Obi J, Rich NE, Parikh ND, Marrero JA, Yopp A, et al. Surveillance imaging and alpha fetoprotein for early detection of hepatocellular carcinoma in patients with cirrhosis: a meta-analysis. *Gastroenterology.* 2018;154(6):1706-18. DOI: 10.1053/j.gastro.2018.01.064
- Mizejewski GJ. Alpha-fetoprotein structure and function: relevance to isoforms, epitopes, and conformational variants. *Exp Biol Med.* 2001;226(5):377-408. DOI: 10.1177/153537020122600503
- Pak S, Takayama T, Yokoyama N, Kato J. Alpha-fetoprotein: an interesting biomarker for hepatology. *Hepatol Int.* 2020;14(5):696-702. DOI: 10.1007/s12072-020-10065-z
- Bader D, Riskin A, Vafsi O, Noter Y, Levin E, Kugelman A, et al. Alpha-fetoprotein in the early neonatal period--a large study and review of the literature. *Clin Chim Acta.* 2004;349(1-2):15-23. DOI: 10.1016/j.cccn.2004.06.020
- Li M, Li H, Li C, Zhou S, Guo L, Liu H, et al. Alpha fetoprotein: the molecular biology of a complex protein and its role in hepatocellular carcinoma. *Clin Transl Oncol.* 2021;23(11):2366-78. DOI: 10.1007/s12094-021-02635-9
- Bergstrand CG, Czar B. Demonstration of a new protein fraction in serum from the human fetus. *Scand J Clin Lab Invest.* 1956;8(2):174-9. DOI: 10.3109/00365515609049266
- Johnson PJ. The role of serum alpha-fetoprotein estimation in the diagnosis and management of hepatocellular carcinoma. *Clin Liver Dis.* 2001;5(1):145-59. DOI: 10.1016/s1089-3261(05)70158-6
- Wang M, Long RE, Comunale MA, Junaidi O, Marrero J, Di Bisceglie AM, et al. Novel fucosylated biomarkers for the early detection of hepatocellular carcinoma. *Cancer Epidemiol Biomarkers Prev.* 2009;18(6):1914-21. DOI: 10.1158/1055-9965.EPI-08-0980
- Zhu WW, Guo JJ, Guo L, Jia HL, Zhu M, Zhang JB, et al. Evaluation of midkine as a diagnostic serum biomarker in hepatocellular carcinoma. *Clin Cancer Res.* 2013;19(14):3944-54. DOI: 10.1158/1078-0432.CCR-12-3363
- Yamashita T, Forgues M, Wang W, Kim JW, Ye Q, Jia H, et al. EpCAM and alpha-fetoprotein expression defines novel prognostic subtypes of hepatocellular carcinoma. *Cancer Res.* 2008;68(5):1451-61. DOI: 10.1158/0008-5472.CAN-07-6013
- Singal AG, Pillai A, Tiro J. Early detection, curative treatment, and survival rates for hepatocellular carcinoma surveillance in patients with cirrhosis: a meta-analysis. *PLoS Med.* 2014;11(4):e1001624. DOI: 10.1371/journal.pmed.1001624
- Vilarinho S, Calvisi DF. New advances in precision medicine for hepatocellular carcinoma recurrence prediction and treatment. *Hepatology.* 2022;75(5):1341-50. DOI: 10.1002/hep.32316
- Kudo M. Alpha-fetoprotein as a biomarker of hepatocellular carcinoma: Revisited. *Hepatol Res.* 2022;52(4):347-56. DOI: 10.1111/hepr.13752
- Sauzay C, Petit A, Bourgeois AM, Barbare JC, Chauffert B, Galmiche A, et al. Alpha-fetoprotein (AFP): A multi-purpose marker in hepatocellular carcinoma. *Clin Chim Acta.* 2016;463:39-44. DOI: 10.1016/j.cca.2016.10.006
- Ayuso C, Rimola J, Vilana R, Burrel M, Darnell A, García-Criado Á, et al. Diagnosis and staging of hepatocellular carcinoma (HCC): current guidelines. *Eur J Radiol.* 2018;101:72-81. DOI: 10.1016/j.ejrad.2018.01.025
- Marrero JA, Kulik LM, Sirlin CB, Zhu AX, Finn RS, Abecassis MM, et al. Diagnosis, staging, and management of hepatocellular carcinoma: 2018 practice guidance by the American Association for the Study of Liver Diseases. *Hepatology.* 2018;68(2):723-50. DOI: 10.1002/hep.29913

22. Atiq O, Kemmer N, Ussman N, McKenna G, Alsaigh N, Malik S, et al. The epidemiology and clinical significance of AFP-negative hepatocellular carcinoma. *J Oncol Pharm Pract.* 2020;26(5):1214-21. DOI: 10.1177/1078155219892027
23. Zhou J, Sun H, Wang Z, Cong W, Wang J, Zeng M, et al. Guidelines for the diagnosis and treatment of hepatocellular carcinoma (2019 edition). *Liver Cancer.* 2020;9(6):682-720. DOI: 10.1159/000509424
24. Biselli M, Andreone P, Gramenzi A, Trevisani F, Cursaro C, Rossi C, et al. Clinical impact of the cutoff value of serum alpha fetoprotein in hepatocellular carcinoma. *World J Gastroenterol.* 2007;13(11):1634-9. DOI: 10.3748/wjg.v13.i11.1634
25. Tayob N, Lok AS, Do KA, Feng Z. Improved detection of hepatocellular carcinoma by using a longitudinal alpha-fetoprotein screening algorithm. *Clin Gastroenterol Hepatol.* 2016;14(3):469-75. DOI: 10.1016/j.cgh.2015.07.049
26. Gopal P, Yopp AC, Waljee AK, Chiang J, Nehra M, Kandunoori P, et al. Factors that affect accuracy of alpha-fetoprotein test in detection of hepatocellular carcinoma in patients with cirrhosis. *Clin Gastroenterol Hepatol.* 2014;12(5):870-7. DOI: 10.1016/j.cgh.2013.09.053
27. Paul SB, Gulati MS, Sreenivas V, Madan K, Gupta AK, Mukhopadhyay S, et al. Evaluating patients with cirrhosis for hepatocellular carcinoma: value of clinical symptomatology, imaging and alpha-fetoprotein. *Oncology.* 2007;72 Suppl 1:117-23. DOI: 10.1159/000111717
28. Tangkijvanich P, Anukulakarnkusol N, Suwangool P, Lertmaharit S, Hanvivatvong O, Kullavanijaya P, et al. Clinical characteristics and prognosis of hepatocellular carcinoma: analysis based on serum alpha-fetoprotein levels. *J Clin Gastroenterol.* 2000;31(4):302-8. DOI: 10.1097/00004836-200012000-00007
29. Zhang J, Chen G, Zhang P, Zhang J, Li X, Gan D, et al. The threshold of alpha-fetoprotein (AFP) for the diagnosis of hepatocellular carcinoma: A systematic review and meta-analysis. *PLoS One.* 2020;15(2):e0228857. DOI: 10.1371/journal.pone.0228857
30. Di Bisceglie AM, Sterling RK, Chung RT, Everhart JE, Dienstag JL, Bonkovsky HL, et al. Serum alpha-fetoprotein levels in patients with advanced hepatitis C: results from the HALT-C Trial. *J Hepatol.* 2005;43(3):434-41. DOI: 10.1016/j.jhep.2005.03.019
31. Han G, Berhane S, Toyoda H, Bettinger D, Elshaarawy O, Chan AWH, et al. Prediction of survival among patients receiving transarterial chemoembolization for hepatocellular carcinoma: a response-based approach. *Hepatology.* 2020;72(1):198-212. DOI: 10.1002/hep.31022
32. Singal AG, Lampertico P, Nahon P. Epidemiology and surveillance for hepatocellular carcinoma: New trends. *J Hepatol.* 2020;72(2):250-61. DOI: 10.1016/j.jhep.2019.08.025
33. European Association for the Study of the Liver. EASL Clinical Practice Guidelines: Management of hepatocellular carcinoma. *J Hepatol.* 2018;69(1):182-236. DOI: 10.1016/j.jhep.2018.03.019
34. Omata M, Cheng AL, Kokudo N, Kudo M, Lee JM, Jia J, et al. Asia-Pacific clinical practice guidelines on the management of hepatocellular carcinoma: a 2017 update. *Hepatol Int.* 2017;11(4):317-70. DOI: 10.1007/s12072-017-9799-9
35. Bruix J, Sherman M. Management of hepatocellular carcinoma: an update. *Hepatology.* 2011;53(3):1020-2. DOI: 10.1002/hep.24199
36. Berhane S, Toyoda H, Tada T, Kumada T, Kagebayashi C, Satomura S, et al. Role of the GALAD and BALAD-2 serologic models in diagnosis of hepatocellular carcinoma and prediction of survival in patients. *Clin Gastroenterol Hepatol.* 2016;14(6):875-86. DOI: 10.1016/j.cgh.2015.12.042
37. Chan MY, She WH, Dai WC, Tsang SH, Chok KS, Chan AC, et al. Prognostic value of preoperative alpha-fetoprotein (AFP) level in patients receiving curative hepatectomy- an analysis of 1,182 patients in Hong Kong. *Transl Gastroenterol Hepatol.* 2019;4:52. DOI: 10.21037/tgh.2019.06.07
38. Chaiteerakij R, Addissie BD, Roberts LR. Update on biomarkers of hepatocellular carcinoma. *Clin Gastroenterol Hepatol.* 2015;13(2):237-45. DOI: 10.1016/j.cgh.2013.10.038
39. Lok AS, Sterling RK, Everhart JE, Wright EC, Hoefs JC, Di Bisceglie AM, et al. Des-gamma-carboxy prothrombin and alpha-fetoprotein as biomarkers for the early detection of hepatocellular carcinoma. *Gastroenterology.* 2010;138(2):493-502. DOI: 10.1053/j.gastro.2009.10.031
40. Chan SL, Mo FK, Johnson PJ, Hui EP, Ma BB, Ho WM, et al. New utility of an old marker: serial alpha-fetoprotein measurement in predicting radiologic response and survival of patients with hepatocellular carcinoma undergoing systemic chemotherapy. *J Clin Oncol.* 2009;27(3):446-52. DOI: 10.1200/JCO.2008.18.8151
41. Nguyen MH, Garcia RT, Simpson PW, Wright TL, Keeffe EB. Racial differences in effectiveness of alpha-fetoprotein for diagnosis of hepatocellular carcinoma in hepatitis C virus cirrhosis. *Hepatology.* 2002;36(2):410-7. DOI: 10.1053/jhep.2002.34744
42. Chan HL, Hui AY, Wong ML, Tse AM, Hung LC, Wong VW, et al. Genotype C hepatitis B virus infection is associated with an increased risk of hepatocellular carcinoma. *Gut.* 2004;53(10):1494-8. DOI: 10.1136/gut.2003.033324
43. Farinati F, Marino D, De Giorgio M, Baldan A, Cantarini M, Cursaro C, et al. Diagnostic and prognostic role of alpha-fetoprotein in hepatocellular carcinoma: both or neither? *Am J Gastroenterol.* 2006;101(3):524-32. DOI: 10.1111/j.1572-0241.2006.00443.x
44. Taketa K. Alpha-fetoprotein: reevaluation in hepatology. *Hepatology.* 1990;12(6):1420-32. DOI: 10.1002/hep.1840120625
45. Murray MJ, Huddart RA, Coleman N. The present and future of serum diagnostic tests for testicular germ cell tumours. *Nat Rev Urol.* 2016;13(12):715-25. DOI: 10.1038/nrurol.2016.170
46. Trevisani F, D'Intino PE, Morselli-Labate AM, Mazzella G, Accogli E, Caraceni P, et al. Serum alpha-fetoprotein for diagnosis of hepatocellular carcinoma in patients with chronic liver disease: influence of HBsAg and anti-HCV status. *J Hepatol.* 2001;34(4):570-5. DOI: 10.1016/s0168-8278(00)00053-2
47. Sterling RK, Wright EC, Morgan TR, Seeff LB, Hoefs JC, Di Bisceglie AM, et al. Frequency of elevated hepatocellular carcinoma (HCC) biomarkers in patients with advanced hepatitis C. *Am J Gastroenterol.* 2012;107(1):64-74. DOI: 10.1038/ajg.2011.312
48. Chen CH, Lin ST, Kuo CL, Nien CK. Clinical significance of elevated alpha-fetoprotein (AFP) in chronic hepatitis C without hepatocellular carcinoma. *Hepatogastroenterology.* 2008;55(85):1423-7. PMID: 18795706
49. Ang SF, Ng ES, Li H, Ong YH, Choo SP, Ngeow J, et al. The Singapore Liver Cancer Recurrence (SLICER) Score for relapse prediction in patients with surgically resected hepatocellular carcinoma. *PLoS One.* 2015;10(4):e0118658. DOI: 10.1371/journal.pone.0118658
50. Kaseb AO, Abaza YM, Roses RE, Hassabo HM, Xiao L, Hassan MM, et al. Perioperative and prognostic features and long-term outcome in patients with fibrolamellar hepatocellular carcinoma. *World J Gastrointest Surg.* 2015;7(7):106-13. DOI: 10.4240/wjgs.v7.i7.106
51. Tateishi R, Yoshida H, Matsuyama Y, Mine N, Kondo Y, Omata M. Diagnostic accuracy of tumor markers for hepatocellular

- carcinoma: a systematic review. *Hepatol Int.* 2008;2(1):17-30. DOI: 10.1007/s12072-007-9038-x
52. Hoshida Y, Nijman SM, Kobayashi M, Chan JA, Brunet JP, Chiang DY, et al. Integrative transcriptome analysis reveals common molecular subclasses of human hepatocellular carcinoma. *Cancer Res.* 2009;69(18):7385-92. DOI: 10.1158/0008-5472.CAN-09-1089
 53. Heimbach JK, Kulik LM, Finn RS, Sirlin CB, Abecassis MM, Roberts LR, et al. AASLD guidelines for the treatment of hepatocellular carcinoma. *Hepatology.* 2018;67(1):358-80. DOI: 10.1002/hep.29086
 54. Simmons O, Fetzer DT, Yokoo T, Marrero JA, Yopp A, Kono Y, et al. Predictors of adequate ultrasound quality for hepatocellular carcinoma surveillance in patients with cirrhosis. *Aliment Pharmacol Ther.* 2017;45(1):169-77. DOI: 10.1111/apt.13841
 55. Cerny M, Chernyak V, Olivieri D, Billiard JS, Murphy-Lavallée J, Kielar AZ, et al. LI-RADS version 2018 ancillary features at MRI. *Radiographics.* 2018;38(7):1973-2001. DOI: 10.1148/rg.2018180052
 56. Tangkijvanich P, Tosukhowong P, Bunyongyod P, Lertmaharit S, Hanvivatvong O, Kullavanijaya P, et al. Alpha-fetoprotein, alpha-fetoprotein-L3, and alpha-fetoprotein-L1 in patients with hepatocellular carcinoma: correlation with clinical and histopathologic features. *J Gastroenterol Hepatol.* 1999;14(5):454-9. DOI: 10.1046/j.1440-1746.1999.01895.x
 57. Chen TM, Huang PT, Tsai MH, Lin LF, Liu CC, Ho KS, et al. Predictors of the survival of advanced hepatocellular carcinoma patients treated with sorafenib. *Oncology.* 2011;80(3-4):216-22. DOI: 10.1159/000328448
 58. Ma WJ, Wang HY, Teng LS. Correlation analysis of preoperative serum alpha-fetoprotein (AFP) level and prognosis of hepatocellular carcinoma (HCC) after hepatectomy. *World J Surg Oncol.* 2013;11:212. DOI: 10.1186/1477-7819-11-212
 59. Shao YY, Liu TH, Hsu C, Lu LC, Shen YC, Lin ZZ, et al. Early alpha-fetoprotein response associated with treatment efficacy of immune checkpoint inhibitors for advanced hepatocellular carcinoma. *Liver Int.* 2019;39(11):2184-9. DOI: 10.1111/liv.14210.
 60. Giannini EG, Marengo S, Borgonovo G, Savarino V, Farinati F, Del Poggio P, et al. Alpha-fetoprotein has no prognostic role in small hepatocellular carcinoma identified during surveillance in compensated cirrhosis. *Hepatology.* 2012;56(4):1371-9. DOI: 10.1002/hep.25814
 61. Sinn DH, Choi GS, Park HC, Kim JM, Kim H, Song KD, et al. Multidisciplinary approach is associated with improved survival of hepatocellular carcinoma patients. *PLoS One.* 2019;14(1):e0210730. DOI: 10.1371/journal.pone.0210730
 62. Chalasani NP, Hayashi PH, Bonkovsky HL, Navarro VJ, Lee WM, Fontana RJ. ACG Clinical Guideline: the diagnosis and management of idiosyncratic drug-induced liver injury. *Am J Gastroenterol.* 2014;109(7):950-66. DOI: 10.1038/ajg.2014.131
 63. Zhang J, Chen G, Zhang P, Zhang J, Li X, Gan D, et al. The threshold of alpha-fetoprotein (AFP) for the diagnosis of hepatocellular carcinoma: A systematic review and meta-analysis. *PLoS One.* 2020;15(2):e0228857. DOI: 10.1371/journal.pone.0228857
 64. Sturgeon CM, Hoffman BR, Chan DW, Ch'ng SL, Hammond E, Hayes DF, et al. National Academy of Clinical Biochemistry Laboratory Medicine Practice Guidelines for use of tumor markers in clinical practice: quality requirements. *Clin Chem.* 2008;54(8):e1-e10. DOI: 10.1373/clinchem.2007.094144
 65. Bridgewater J, Galle PR, Khan SA, Llovet JM, Park JW, Patel T, et al. Guidelines for the diagnosis and management of intrahepatic cholangiocarcinoma. *J Hepatol.* 2014;60(6):1268-89. DOI: 10.1016/j.jhep.2014.01.021
 66. Cohen JD, Li L, Wang Y, Thoburn C, Afsari B, Danilova L, et al. Detection and localization of surgically resectable cancers with a multi-analyte blood test. *Science.* 2018;359(6378):926-30. DOI: 10.1126/science.aar3247
 67. Ioannou GN, Tang W, Beste LA, Tincopa MA, Su GL, Van T, et al. Assessment of a deep learning model to predict hepatocellular carcinoma in patients with hepatitis C cirrhosis. *JAMA Netw Open.* 2020;3(9):e2015626. DOI: 10.1001/jamanetworkopen.2020.15626
 68. Wolf E, Rich NE, Marrero JA, Parikh ND, Singal AG. Use of hepatocellular carcinoma surveillance in patients with cirrhosis: A systematic review and meta-analysis. *Hepatology.* 2021;73(2):713-25. DOI: 10.1002/hep.31309

How to cite this article

Adeyemo, J. A., Oladosu, M. A., & Abah, M. A. (2026). Alpha-fetoprotein in hepatocellular carcinoma: Diagnostic value, prognostic significance and clinical limitations. *Science Archives*, 7(2), 61–73. <https://doi.org/10.47587/SA.2026.7205>

This work is licensed under a [Creative Commons Attribution 4.0 International License](https://creativecommons.org/licenses/by/4.0/)

